

Medical Quiz

Saeed Alhindi, MD, CABS, FRCSI*

A three-year-old boy presented with abdominal pain of 3-days of duration. This pain is associated with vomiting, fever and loss of appetite. The patient had radiological investigations. Look at the figures below and answer the following questions.

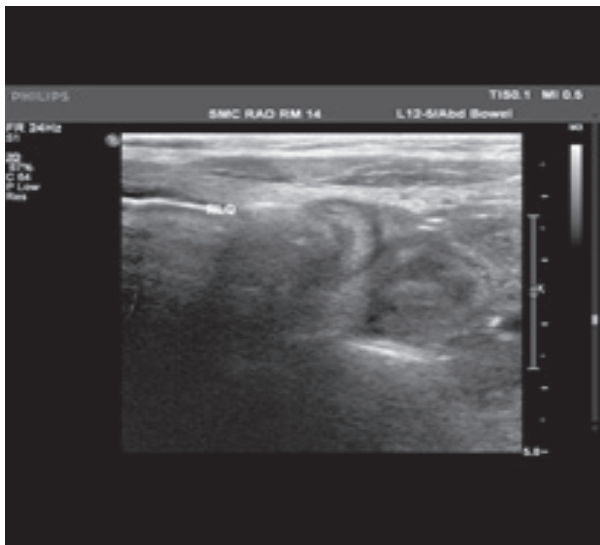

Figure 1

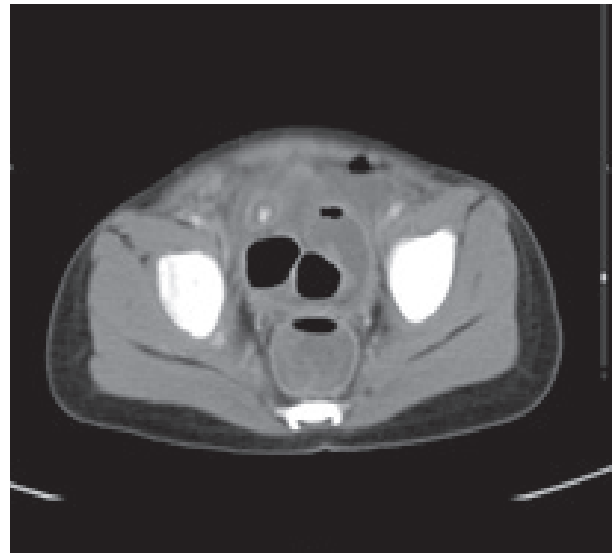


Figure 2

- Q1. Identify the radiological test in figures 1 and 2.
- Q2. Describe the findings in the figures.
- Q3. What is the diagnosis and management of this case?

Answers on page 195

* Assistant Professor, Arabian Gulf University
Consultant Pediatric Surgeon, Salmaniya Medical Complex
P.O. Box 12
Kingdom of Bahrain
E-mail: sjalhindi@yahoo.com, sjalhindi@gmail.com