

## Idiopathic Complete Heart Block with Early Post Pacemaker Lead Failure in a Child

Arun Bableshwar, MD FPC\* Suad Al Amer MD, DCH, SSC-P, SF-(Ped)\*\* Mohammad Amin MD, MRCP (UK), FHRS, CEPS-AC, CCD\*\*\* Neale Nicola Kalis, MBCH (Stell) FCP (Ped SA), MMed (Ped)\*\*\*\*

**Acute onset Complete Heart Block (CHB) is a rare entity in children. A seven-year-old child with no recent history of infection presented with two episodes of syncope while at rest. ECG showed a high second degree atrioventricular (AV) block which progressed to complete heart block over 24 hours. Due to life-threatening frequent Stokes-Adams syncopal attacks, permanent epicardial pacemaker implantation was performed. Twenty hours post-surgery, the child had repeated attacks of Stokes-Adams syncope. Telemetry revealed complete heart block, heart rate 40/min with the absence of pacing spikes. Pacemaker assessment showed a high sensing threshold suggestive of lead failure due to exit block. He underwent urgent re-surgery and replacement of epicardial passive buttons. The child was observed for further 24 hours, who remained stable and assessment of pacemaker confirmed acceptable settings. He was discharged in satisfactory condition.**

*Bahrain Med Bull 2020; 42 (3): 218 - 220*

Acute onset of Complete Heart Block (CHB) is a rare entity in children. Acquired heart block in children has multifactorial causes. Laboratory investigations could fail to detect underlying etiology. Third-degree heart block is often irreversible, has high morbidity and requires pacemaker implantation in most cases<sup>1</sup>.

CHB in children can be congenital or acquired and of first, second or third degree. The first-degree block found in asymptomatic children is defined as PR time prolongation more than 98th percentile for age. The second-degree block is of two types: Mobitz type-1 and type-2. Mobitz type-1 involves progressive PR time prolongation followed by a dropped beat (Wenkebach phenomenon). Mobitz type-2 is without progressive lengthening of the PR interval but characterized by a failure of ventricular conduction of P waves. The third-degree block involves the complete dissociation of P waves and QRS complexes. High-degree atrio-ventricular (AV) block encompasses both second-degree Mobitz type-2 and third-degree AV block<sup>2</sup>. Delayed conduction of electrical signals from atria to ventricles results in bradycardia, which

could decrease the cardiac output to cause syncope, called Stokes-Adams syncope<sup>3</sup>.

The aim of this presentation is to report a case of an acquired complete heart block, pacemaker indications in childhood and causes of lead failures.

### THE CASE

A seven-year-old boy was admitted with history of two episodes of syncope while at rest at home. He did not complain of any chest pain, breathing difficulty or palpitations. There was a history of brief sore throat three weeks previously and he was treated with oral antibiotics. Family history revealed no connective tissue disease, heart blocks, congenital heart disease or sudden cardiac deaths. Parent's marriage was second-degree consanguineous.

The patient presented with cardiogenic shock, sweating, cool peripheries and low blood pressure of 78/46mmHg. ECG

---

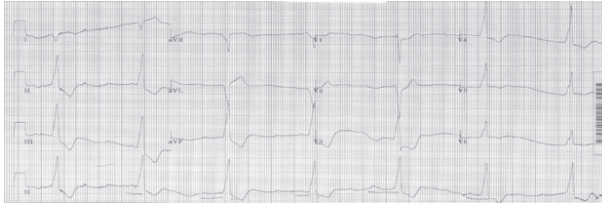\* Senior Resident  
Mohammad bin Khalifa bin Salman Al-Khalifa Cardiac Centre  
Bahrain Defense Force Hospital

\*\* Consultant Pediatric Cardiologist  
Mohammad bin Khalifa bin Salman Al-Khalifa Cardiac Centre  
Bahrain Defense Force Hospital  
Senior Lecturer  
Royal College of Surgeons of Ireland – Bahrain

\*\*\* Consultant Cardiologist  
Mohammad bin Khalifa bin Salman Al-Khalifa Cardiac Centre  
Bahrain Defense Force Hospital  
Senior Lecturer  
Royal College of Surgeons of Ireland – Bahrain

\*\*\*\* Consultant Pediatric Cardiologist  
Mohammad bin Khalifa bin Salman Al-Khalifa Cardiac Centre  
Bahrain Defense Force Hospital  
Associate Professor  
Royal College of Surgeons of Ireland – Bahrain  
Kingdom of Bahrain  
E-mail: nnkalis@batelco.com.bh

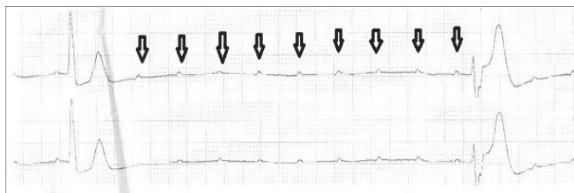
showed a heart rate of 42/minute, complete heart block with a wide QRS escape rhythm, see figure 1. He was conscious and responsive. Cardiovascular and systemic examinations were normal.



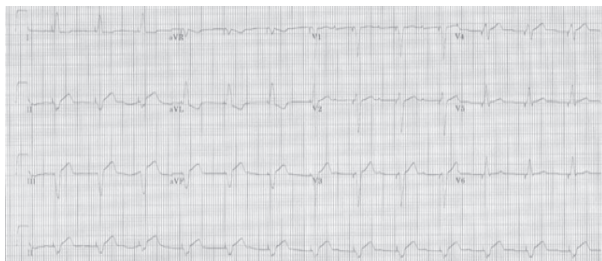**Figure 1: Complete Heart Block with Heart Rate of 42/minute and Wide QRS Escape Rhythm**

Laboratory studies revealed white blood counts of  $9.00 \times 10^9/L$  with 72% lymphocytes, ESR/CRP, serum electrolytes and cardiac enzymes were all normal. Chest X-ray showed normal cardiac silhouette and lung fields. Bedside echocardiography revealed a structurally and functionally normal heart. Viral serology studies were normal. ANA, DsDNA and Anti-Ro/La antibodies were negative. The ECG of both parents were normal.

He was initially managed with inotropic support but had multiple episodes of Stokes-Adams syncope. Telemetry showed complete heart block with the lowest recorded heart rate of 15/minute, see figure 2. In view of symptomatic and life-threatening bradycardia, the child underwent urgent surgical implantation of epicardial pacemaker (PM) (Etrinsa-6-SR, Biotronik, Germany) with St. Jude leads on the right ventricular surface via subxiphoid approach and battery was placed in the lateral abdominal wall. PM was programmed to VVI (Ventricle paced and Ventricle sensed) mode, rate of 80/minute with capture threshold of 1.2Volts at 0.4msec and impedance of 242 Ohms. Post-surgery, ECG showed regular pacing spikes and normal vitals, see figure 3. Chest X-ray and echocardiography revealed no pericardial effusion and normal left ventricular ejection fraction.



**Figure 2: Telemetry Shows Complete Heart Block with Ventricular Rate of 15/min (Arrows Depict Isolated P Waves)**



**Figure 3: ECG Post Pacemaker Shows Regular Pacing Spikes**

Twenty hours post-surgery, the child had repeated attacks of Stokes-Adams syncope. Telemetry revealed complete heart block, heart rate 40/minute with the absence of pacing spikes. Chest X-ray showed the same lead position as before. Urgent bedside PM assessment revealed lead impedance of 585 Ohms but very high capture threshold, suggestive of lead failure due to exit block. He underwent urgent surgical replacement of previous lead with a Medtronic Myodex™ fixation screw lead.

Postoperatively, the child was stable with acceptable capture threshold (1.2 volts at 0.4 msec), impedance 437 Ohms and ECG showed regular pacing spikes. The child was observed for a further 24 hours, found to be stable and a recheck of PM was done to confirm settings and then the patient was discharged.

Follow-up of the patient after four weeks showed 25% pacing requirement, RV: 3.3mV with a resistance of 331b Ohms and capture threshold of 2.2V at 0.4ms.

## DISCUSSION

Heart blocks occur rarely with cardiac interventions during diagnostic or therapeutic procedures, such as atrial septal defect (ASD) or ventricle septal defect (VSD) device closures. Children with Kearns Sayre syndrome, glycogen storage disorders, and myotonic dystrophy can also present with progressive heart block. Recently, a spectrum of familial heart blocks have been classified as Progressive Cardiac Conduction Disorder (PCCD). Onset is usually below 50 years of age with family history of conduction disorders and structurally normal heart. Several genes such as SCN5A, SCN1B, SCN10A, TRPM4, and KCNK17 have been associated with this condition. It is an autosomal-dominantly inherited disease of the His-Purkinje system<sup>4</sup>.

The treatment goal for a complete heart block is to maintain adequate cardiac output. Advanced second degree or complete heart block with symptomatic bradycardia, pacing is indicated in acquired AV block, third-degree or high second-degree block without symptoms but with wide QRS escape rhythm<sup>5</sup>.

Cardiac pacing using an external battery pulse generator has long been used. PM leads are either placed on the epicardial or endocardial surfaces of the cardiac chambers. In early childhood due to low body weight, difficult venous access and future somatic growth, PMs are commonly surgically implanted on the epicardial surfaces. Patients with a single ventricle, prosthetic valves are also candidates for epicardial pacing. In older children and adolescents, PM leads can safely be placed via a trans-venous approach on endocardial surfaces. Such endocardial leads can cause venous thrombosis, endocarditis or damage to atrioventricular valves<sup>6</sup>. Both epicardial and endocardial leads use either conventional (non-steroid eluting) or steroid eluting (SE). The leads are of the metallic hook or screw type.

Steroid eluting leads were introduced in the 1980s and have shown advantages compared to non-steroid eluting (NSE); NSE are long-term, low thresholds and protect from inflammation at implantation site<sup>7</sup>.

Pacemakers usually are safe in children, the majority of

complications are lead-related. Epicardial leads have a higher rate of lead failures. Lead failures are defined as discontinuity of pacing or lead replacement due to very high pacing threshold, exit-block, sensing abnormalities, lead dislodgement, fracture or infection<sup>8</sup>.

Long-term studies on lead failures showed that younger age (<12 years), structural heart defects and epicardial leads have a higher incidence of lead malfunction<sup>8,9</sup>. Conventional epicardial leads had survival of 16% compared to 34% steroid eluting leads for 2.4 years<sup>10,11,12</sup>. Long-term lead survival rates range from 58% to 91% at 5 years and 30% to 72% at 10 years<sup>13</sup>.

Dexamethasone coating of leads reduces inflammation at the epicardial surface and decreases the stimulation threshold and risk of exit block. Both Cohen et al and Thomson et al reported favorable long-term survival rates of SE epicardial leads at 83% and 76% at 5 years<sup>11,12</sup>. In both studies, long-term exit block between epicardial SE and endocardial SE leads were comparable.

Exit block or elevation of stimulation threshold in epicardial leads was the most common complication in a study by Murayama et al<sup>8</sup>. A higher incidence of exit block was reported in children with congenital heart diseases by Fortescue et al<sup>9</sup>. Other reasons for lead failure are sensing issues, lead fracture, lead displacement and infection.

In our case, the child presented acutely with symptomatic bradycardia and Stokes-Adams syncope which is an indication for permanent pacing. Due to small patient size and age, we decided for epicardial PM implantation. However, we also experienced an early PM lead exit block, which needed urgent replacement of the leads.

## CONCLUSION

**Idiopathic complete heart block in pediatric age group is a challenging. Early diagnosis and PM implantation is lifesaving in case of symptomatic complete heart block. The choice of epicardial or endocardial pacing in children should be individualized. Steroid eluting epicardial PM leads have similar outcomes as endocardial ones and are currently the standard of care in children. PM lead failures especially exit block are fairly common in children and should be treated early.**

---

**Author Contribution:** All authors share equal effort contribution towards (1) substantial contributions to conception and design, analysis and interpretation of data; (2) drafting the article and revising it critically for important intellectual content; and (3) final approval of the manuscript version to be published. Yes.

**Potential Conflicts of Interest:** None.

**Competing Interest:** None.

**Sponsorship:** None.

**Acceptance Date:** 14 May 2020.

**Ethical Approval:** Approved by the Ethical Committee, Mohammed bin Khalifa bin Salman Al-Khalifa Cardiac Center, Bahrain Defence Force Hospital, Bahrain.

## REFERENCES

1. Michaelsson M, Riesenfeld T, Jonzon A. Natural History of Congenital Complete Atrioventricular Block. *Pacing Clin Electrophysiol* 1997; 20(8 Pt 2):2098-101.
2. Robles de Medina EO, Bernard R, Coumel P, et al. Definition of Terms Related to Cardiac Rhythm. *Eur J Cardiol* 1978; 8:127-144.
3. Gilchrist AR. Clinical Aspects of High Grade Heart Block. *Scott Med J* 1958; 3:53-75.
4. Baruteau AE, Pass RH, Thambo JB, et al. Congenital and Childhood Atrioventricular Blocks: Pathophysiology and Contemporary Management. *Eur J Pediatr* 2016; 175(9): 1235-1248.
5. Brignole M, Auricchio A, Baron-Eskivas G, et al. ESC Guidelines on Cardiac Pacing and Cardiac Resynchronization Therapy: The Task Force on Cardiac Pacing and Resynchronization Therapy of the European Society of Cardiology (ESC). Developed in Collaboration with the European Heart Rhythm Association (EHRA), *EP Europace* 2013; 15(8): 1070-1118.
6. Sliz NB Jr, Johns JA. Cardiac Pacing in Infants and Children. *Cardiology in Review* 2000; 8(4):223-239.
7. Mond HG, Helland JR, Stokes K, et al. The Electrode-tissue Interface: The Revolutionary Role of Steroid-Elution. *Pacing Clin Electrophysiol* 2014; 37:1232-1249.
8. Murayama H, Maeda M, Sakurai H, et al. Predictors Affecting Durability of Epicardial Pacemaker Leads in Pediatric Patients. *The Journal of Thoracic and Cardiovascular Surgery* 2008; 135(2): 361-366.
9. Fortescue EB, Berul CI, Cecchin F, et al. Patient, Procedural, and Hardware Factors associated with Pacemaker Lead Failures in Pediatrics and Congenital Heart Disease. *Heart Rhythm* 2004; 1(2): 150-159.
10. Silvetti MS, Drago F, Grutter G, et al. Twenty Years of Cardiac Pacing in Pediatric Age: 515 Pacemakers and 480 Leads Implanted in 292 Patients. *Europace* 2006; 8(7): 530-536.
11. Cohen MI, Bush DM, Vetter VL, et al. Permanent Epicardial Pacing in Pediatric Patients. Seventeen Years of Experience and 1200 Outpatient Visits. *Circulation* 2001 ; 103(21): 2585-2590.
12. Thomson JDR, Blackburn ME, van Doorn C, et al. Pacing Activity, Patient and Lead Survival Over 20 Years of Permanent Epicardial Pacing in Children. *Annals of Thoracic Surgery* 2004; 77(4): 1366-1370.
13. Osama RS, Ayman D, Aboulmaaty MM. Permanent Pacing in Infants and Children: A Single Center Experience in Implantation and Follow Up. *The Egyptian Heart Journal* 2011; 63(3-4): 183-189.
14. Odim J, Suckow B, Saedi B, et al. Equivalent Performance of Epicardial Versus Endocardial Permanent Pacing in Children: A Single Institution and Manufacturer Experience. <https://www.semanticscholar.org/paper/Performance-of-Epicardial-Versus-ndocardial-Pacing-Odim-Suckow/e1040721a8b3179fd81c5e3ecd2175f8e4785ecc> Accessed in April 2020.