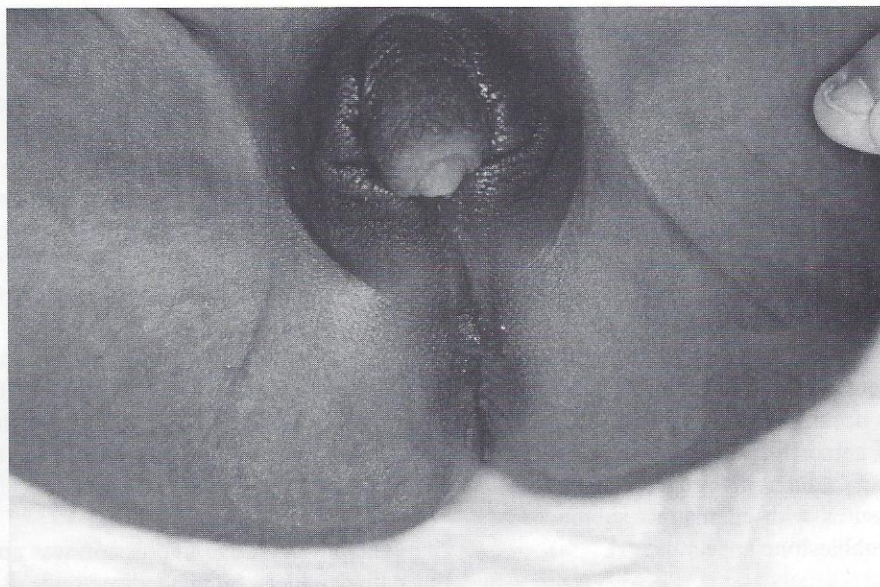


Medical Quiz

Shabih Manzar, MD, FAAP, MRCPH (Associate)



The photograph is showing the genitalia of a newborn infant.

- Q1. What is your diagnosis?
- Q2. What is the etiology?
- Q3. What is the differential diagnosis?

Answers on page no. 155