

Subacute Sclerosing Panencephalitis in a Child

Ayman Khalil Ebrahim, MBBS, CABP* Fatima Neama Mahmood, MBBS, CABP**

Subacute sclerosing panencephalitis (SSPE) is a progressive neurological disease affecting children and adolescents. The etiology is proven to be due to measles virus which causes persistent central nervous system infection. SSPE is classified under the category of progressive myoclonic epilepsy syndromes.

This group of disorders characterized by progressive dementia, cognitive decline and myoclonic epilepsy are frequently resistant to anti epileptic medications.

Although SSPE has generally a poor prognosis, several studies showed variable response to antiviral therapy and Interferon Alpha resulting into stabilization of the disease. In the era of measles vaccination program the incidence of the disease dropped dramatically in USA¹.

We are reporting as far as we believe the first child discovered to have SSPE in the Kingdom of Bahrain. The child presented to the pediatric neurology department with new onset seizures and progressive decline in her school performance. Examination and further investigation proved that the child was suffering from SSPE.

Bahrain Med Bull 2007; 29(4):

Historically SSPE was first reported by Dawson in 1933 based on his neuropathological studies; he used the term inclusion body encephalitis². In 1945, Van Bogaert found glial proliferation and leukomalacia changes in a brain biopsy and he suggested the term of SSPE³.

It was not until 1969 that two groups working independently isolated measles virus by co culturing SSPE brain tissue with cell line susceptible to measles virus infection⁴.

The diagnosis of SSPE as proposed by Dyken et al is based mainly on the following criteria: clinical manifestations, typical EEG findings, positive measles antibodies in serum and CSF and / or positive oligoclonal band, MRI brain changes and finally brain biopsy suggestive of panencephalitis. Three elements of the previously mentioned are considered reliable criteria for SSPE diagnosis⁵.

* Chief resident, Pediatric Neurologist

** Consultant Pediatric Neurologist
Salmaniya Medical Complex
Kingdom of Bahrain

The world wide incidence of SSPE is 1:1000, 000.

Saha et al reported an annual incidence of 21 per million in India, in comparison with 2.4 per million in the Middle East^{6,7}. In the United States, routine measles virus vaccination of children has reduced the incidence from 3.5 cases per million under 20 years of age in 1960 to 0.06 cases per million in 1980⁸.

THE CASE

A ten year old Bahraini girl presented with history of myoclonic body jerks involving the upper limbs and facial muscles for six months. These myoclonic jerks were involuntary, more frequent during wakefulness and less frequent during sleep.

Initially, these myoclonic jerks were infrequent but became worse after one year. Currently, it is repeated more than hundred times per day; there is no clear loss of consciousness or eye deviation. Other seizure types described by parents include generalized tonic-clonic seizures and atonic seizures. The child had multiple antiepileptic medications; her current medications are: Levetiracetam, Lamotrigine and Topiramate. She had had valproate and clonazepam.

The drop attacks and generalized tonic-clonic seizures were reasonably controlled but the myoclonic jerks continued to occur frequently. During the course of the illness, the patient showed clear decline in her educational performance with poor attention span and emotional instability. No clear visual and hearing impairment was noted and ambulation was maintained. Past medical history was unremarkable, except that she had measles at around one year of age; the patient was fully vaccinated including MMR vaccine.

At eight years of age, she was involved in a road traffic accident and lost consciousness. The patient was admitted for five days, but there was no intracranial hemorrhage and no neurological deficit after discharge.

Family history was negative for epilepsy or other chronic neurological disorders. The patients' mini mental examination was on the lower side with non fluent slurred speech; there was no ophthalmoplegia and the rest of cranial nerves were normal. Fundoscopic examination was normal.

Motor examination showed pyramidal signs in the lower limbs with brisk deep tendon reflexes and upgoing plantares; the gait was maintained; no ataxia, apraxia, organomegaly_ or neurocutaneous stigmata were noticed. Systemic examination was unremarkable.

Routine blood investigation including complete blood count, renal profile and hepatic profile were normal. Serum lactate, tandem mass spectroscopy and very long chain fatty acid levels were normal.

MRI brain showed minimal parietal and occipital leukomalacia.

Digital acquired EEG showed paroxysmal activity in the form of generalized giant slow wave complexes which were time locked to the myoclonic jerks, and occurred at 4-6 seconds interval giving the typical periodic pattern which is seen in SSPE, see figure 1, 2.

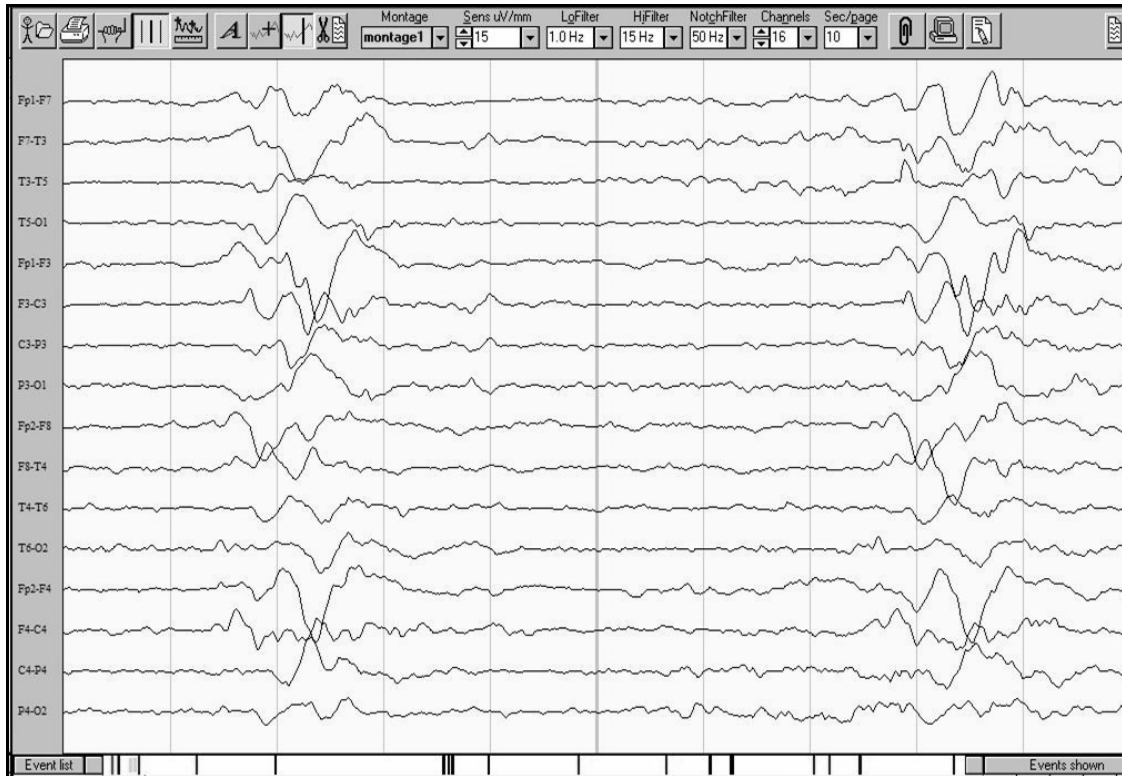


Figure 1: This is an EEG record during wakefulness, there is posterior background slowing with recurrent bursts of generalized sharp wave complexes which were time locked with myoclonic jerks

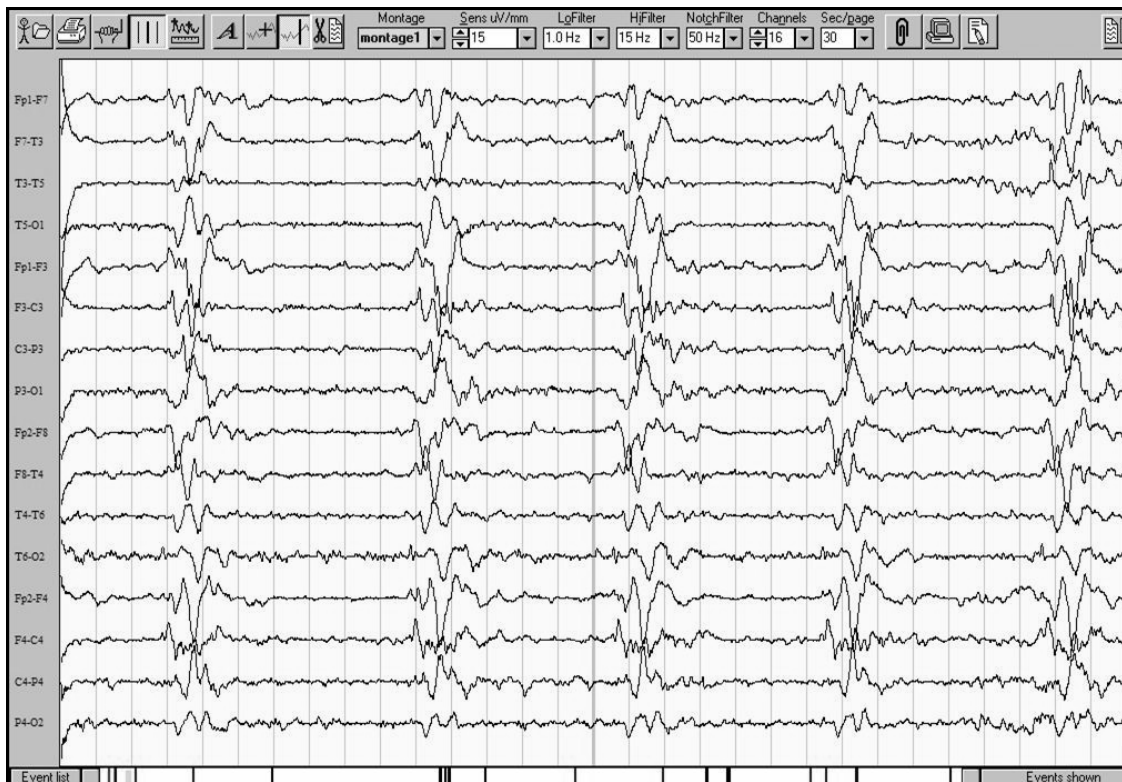

Figure 2: In this EEG record the sweep had been changed to include 30 seconds per page to appreciate the periodic pattern of discharges which is noted every 4-6 seconds

Serology for measles antibodies showed high IgG levels and CSF oligoclonal band was positive indicating intrathecal immunoglobulin synthesis.

The electron microscopy examination of the skin biopsy looking for intracellular inclusion or lysosomal deposition of neuronal ceroid lipofuscinosis and Lafora body disease was negative.

DISCUSSION

SSPE is a progressive neurological disorder caused by persistent measles infection and failure to clear up primary infection due to defective measles virus replication cycle.

The mutated measles genome produces abnormal matrix protein (M-protein) which is important for viral budding and establishing extracellular infection. The preserved hemagglutinin and fusion protein allow spreading of measles virus from cell to cell⁹.

SSPE patients develop a hyperimmune response to measles virus, which fails to control persistent infection¹⁰.

The patients go into several stages.

In stage I, behavioral and intellectual changes are noted; rarely SSPE is diagnosed at this stage^{11,12}.

In stage II, continued intellectual deterioration and onset of typical pattern jerk, both are hallmarks of SSPE. Visual impairment and dressing apraxia may be apparent indicating parieto-occipital involvement¹³.

In stage III, prominent hyperkinetic movements, chorioathetosis are noted indicating basal ganglia involvement. Ambulation is usually clearly affected at this stage. Autonomic dysfunction is a prominent feature¹⁴.

In stage IV, the patients become completely bedridden, the myoclonic jerks and seizures may disappear with the appearance of pathological laughter, persistence of autonomic dysfunction and startle reflex.

In this case, the patient was in stage II. The progression of symptoms from stage I-IV takes about 1-3 years in 80% of cases.

Ten percent of patients, develop slower progressive course, some may survive up to 10 years; but in another 10%, the disease has a more fulminant course¹⁵.

EEG findings are quite characteristic of SSPE. The slow wave complexes occur in a periodic pattern with interburst interval of 4-12 seconds, the jerks are time locked to the complexes. With the progression of the disease, the interburst interval gets shorter with further background activity slowing. Neuroimaging study correlates with the stage of the disease^{16,17}. The white matter changes progress from occipital lobe to the frontal lobe, with subsequent loss of white matter volume. Basal ganglia show abnormalities. In neuroimaging, we can see areas of wedge like appearance of cortical and subcortical white matter involvement mimicking stroke¹⁸. Positive measles antibodies in serum and CSF are confirmatory tests, positive oligoclonal band in the CSF indicates intrathecal immunoglobulin synthesis.

The viral burden between patients differed up to four fold by quantitative PCR and corresponded with detection of measles virus protein. The level of both viral RNA and antigen in the brain may correlate with disease progression¹⁹.

There is no curative treatment of the disease, virtually all patients are dead within 10 years¹². In another series, 5% of patients went into remission for a variable duration but subsequently relapsed and died¹¹.

Several therapeutic trials were conducted. Gascon treated 18 patients with Inosiplex and intraventricular Interferon Alpha, 44% of patients improved or stabilized²⁰.

In this case, the patient had clear cognitive decline, as well as the typical pattern jerk which is peculiar to SSPE. The EEG was diagnostic; it showed clearly the periodic pattern of paroxysmal discharges.

The introduction of measles vaccination program reduced the SSPE incidence. There is no proof that SSPE caused by measles vaccine as it was thought by some.

The possible mechanism of SSPE in vaccinated children is either due to the preceding primary measles infection or aborted vaccine. Currently, the patient has follow up with neurology service and infectious team was involved.

CONCLUSION

We are reporting a case of SSPE diagnosed and confirmed through serology and neuroimaging. Subacute sclerosing panencephalitis is a rare complication of measles infection. We need to keep it in mind during evaluation of any child presenting with progressive myoclonic epilepsy and dementia to seek a history of previous measles infection as it may cause a latent infection. Although the treatment options are not promising but the introduction of measles vaccination program reduced the prevalence of the disease. This case is probably the first reported case in Kingdom of Bahrain.

REFERENCES

١. Jabbour JT, Duenos DA, Sever JL, et al. Epidemiology of Subacute Sclerosing Panencephalitis (SSPE): Report of the SSPE Registry. *JAMA* 1972; 220:959-62.
٢. Dawson JR. Cellular Inclusions in Cerebral Lesions in Lethargic Encephalitis. *Am J Pathol* 1933; 9:7-15.
٣. Van Bogaert L. Une Leucoencéphalite Sclérosante Subaigüe. *J Neurol Neurosurg Psychiatry* 1945; 8:101-20.
٤. Horta-Barbosa L, Fucillo DA, London WT, et al. Isolation of Measles Virus from Brain Cell Cultures of Two Patients with Subacute Sclerosing Panencephalitis. *Proc Soc Exp Biol Med* 1969; 132:272-7.
٥. Dyken PR. Subacute Sclerosing Panencephalitis. *Neurol Clin* 1985; 3:179-95.
٦. Saha V, John TJ, Mukundan P, et al. High Incidence of Subacute Sclerosing Panencephalitis in South India. *Epidemiol Infect* 1990; 104:151-6.
٧. Radhakrishnan K, Thacker AK, Maloo JC, et al. Descriptive Epidemiology of Some Rare Neurological Diseases in Benghazi, Libya. *Neuroepidemiology* 1988; 7:159-64.
٨. Centers for Disease Control. Subacute Sclerosing Panencephalitis Surveillance-United states. *MMWR Morb Mortal Wkly Rep* 1982; 31:585-8.
٩. Baczkko K, Liebert UG, Billeter M, et al. Expression of Defective Measles Virus Genes in Brain Tissues of Patients with Subacute Sclerosing Panencephalitis. *J Virol* 1986; 59:472-8.
١٠. Mehta PD, Thomar H, Kulczycki J, et al. Immune Response in Subacute

- Sclerosing Panencephalitis. *Ann N Y Acad Sci* 1994; 724:378-84.
١١. Risk WS, Haddad FS. The Variable Natural History of Subacute Sclerosing Panencephalitis: A Study of 118 Cases from the Middle East. *Arch Neurol* 1979; 36:610-4.
 ١٢. Kayal M, Varghese ST, Balhara YP. Psychiatric Manifestation of SSPE. *J Neuropsychiatry Clin Neurosci.* 2006; 18(4):560.
 ١٣. Begeer JH, Meihuizen de Regt MJ, HogenEsch I, et al. Progressive Neurological Deficit in Children with Spina Bifida Aperta. *Zeitschr Kinderchirurg* 1986; 41(1):13-5.
 ١٤. Dyken PR, Cunningham SC, Ward LC. Changing Character of Subacute Sclerosing Panencephalitis in the United States. *Pediatr Neurol* 1989; 5:339-41.
 ١٥. Graves MC. Subacute Sclerosing Panencephalitis. *Neurol Clin N Am* 1984; 2: 267-80.
 ١٦. Bohlega S, Al-Kawi MX. Subacute Sclerosing Panencephalitis: Imaging and Clinical Correlation. *J Neuroimag* 1994; 4:71-6.
 ١٧. Oguz KK, Celebi A, Anlar B. MR Imaging, Diffusion-weighted Imaging and MR Spectroscopy Finding in Acute Rapidly Progressive Subacute Sclerosing Panencephalitis. *Brain Dev.*2007; 29(5):306-11.
 ١٨. Takahashi M, Abe K, Fujimura H, et al. A Case of SSPE that Showed Watershed Infarction Like Image on MRI Initially and Progressed to Whole Brain Atrophy. *Rinsho Shinkeigaku* 1991; 31:554-6.
 ١٩. Kuhne Simmonds M, Brown DW, Jin L. Measles Viral Load May Reflect SSPE Disease Progression. *Virol J.* 2006; 21:3-49.
 ٢٠. Gascon G, Yamani S, Crowell J, et al. Combined Oral Isoprinosine-Intraventricular Alpha-interferon Therapy for Subacute Sclerosing Panencephalitis. *Brain Dev* 1993; 15:346-55.