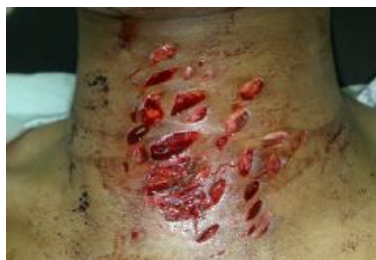

## Medical Quiz

Seema Abbas Hussain, LRCP, SI, MB, BCh, BAO\* Nabeel H Tammam, FRCSEd\*\*

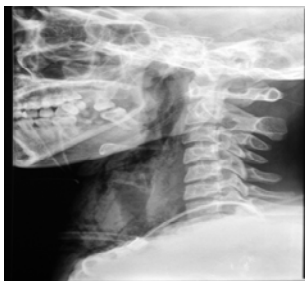A Twenty-Five year old Ethiopian female works as a house-maid for a Bahraini family for the past 7 months.

She was presented to the A and E department in the following state. Clinically she was stable, maintaining her blood pressure at 128/72 mmHg, pulse rate at 107 bpm, and a normal temperature. Patient sustained her injuries in an attempt to suicide with a small kitchen knife, see Figure 1.

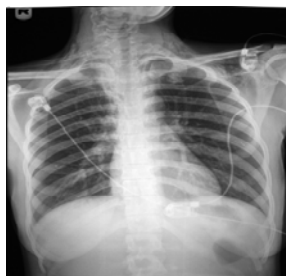

**Figure 1**

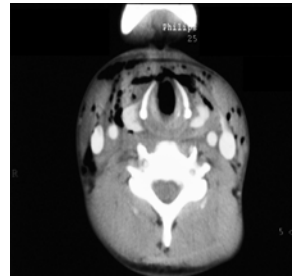
The following radiographic investigations were taken. Lateral neck and Chest X-rays, see Figures 2 and 3. CT scans of neck and chest, see Figures 4 and 5.



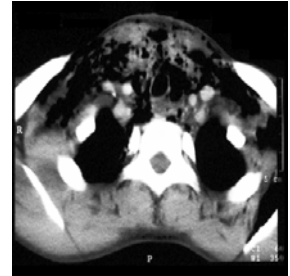
**Figure 2**



**Figure 3**



**Figure 4**



**Figure 5**

**Q.1.** What is your clinical impression?

**Q.2.** Describe the radiological findings on the plain X-rays and CT scans of the neck and chest.

**Q.3.** Outline the management protocol for this patient.

