

## **Composite 3 Layers Tympanoplasty - Promising and Reliable Technique for Management of Dry Central Tympanic Membrane Perforation**

Hesham Yousif Ali Hasan, MD, FRCS (Ed)\* Shilpa Prabhu, MBBS, DLO\*\*

**Numerous graft materials and methods of placement have been described to reconstruct the tympanic membrane. Cartilage was shown both experimentally and clinically to be well tolerated by the middle ear and has long-term survival.**

**A twelve-year-old female presented with history of recurrent episodes of right ear pain and discharge. She experienced slight hearing impairment in the right ear. On examination, she was found to have perforation in antero-inferior quadrant of tympanic membrane of the right ear which was operated successfully with a new technique utilizing a composite 3 layers graft (Perichondrium-Cartilage-Perichondrium) via transcanal approach.**

***Bahrain Med Bull 2013; 35(4):***

The tympanic membrane is a cornerstone in the physiology of hearing as well as in the pathophysiology of middle ear chronic inflammatory diseases<sup>1</sup>. Numerous graft materials and tympanic reconstruction techniques have been advocated<sup>2</sup>. Skin, perichondrium, vein, fascia, dura mater and cartilage have all been described as graft materials for closure of tympanic perforations with variable reported degrees of success<sup>3-11</sup>. However, atrophy and subsequent failure in post-operative period encountered with other grafting materials, cartilage graft was found to be more rigid and durable. Although one might anticipate a significant conductive hearing loss with cartilage, due to its rigidity, it is this quality that tends to resist resorption and retraction even in the milieu of continuous eustachian tube dysfunction. Cartilage was shown both experimentally and clinically to be well-tolerated by the middle ear and its long-term survival to be the norm still; this repair does compromise the audiological outcome compared to other grafts' repair<sup>12-15</sup>.

The aim of this case presentation is to report a novel new technique utilizing composite 3 layers graft (Perichondrium-Cartilage-Perichondrium) that was utilized successfully in the management of tympanic perforation via transcanal approach.

---

\* HOD & Consultant ENT Surgeon

\*\* Senior Resident

Department of ENT

BDF Hospital

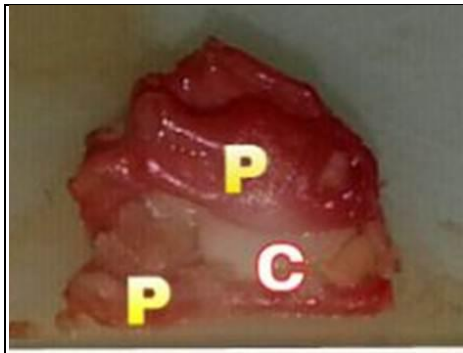
Kingdom Bahrain

Email: drshilent@gmail.com; heshambdf@hotmail.com

## THE CASE

A twelve-year-old female presented with history of recurrent episodes of right otalgia and otorrhea. She also experienced slight hearing impairment. Her past history revealed Grommet insertion, which was extruded spontaneously. On examination, she was initially found to have a wet 30% perforation in antero-inferior quadrant of tympanic membrane, which dried up upon subsequent topical treatment. Pure tone audiometry showed conductive hearing loss of moderate severity.

Transcanal cartilage tympanoplasty under general anesthesia was planned considering her age and clinical presentation. Topical lidocaine 2% and epinephrine 1:100000 were infiltrated into tragus and external auditory canal. An island of tragal cartilage was harvested corresponding to the size of perforation. A bigger portion of both ventral and dorsal perichondrium was left attached and got harvested en bloc, see figure 1. Cosmesis was attended by placing the vertical skin incision medially at tragal edge and by leaving 2 mm-frame of undisturbed tragal cartilage.



**Figure 1: Harvested Graft Cartilage with Ventral and Dorsal Perichondrium**

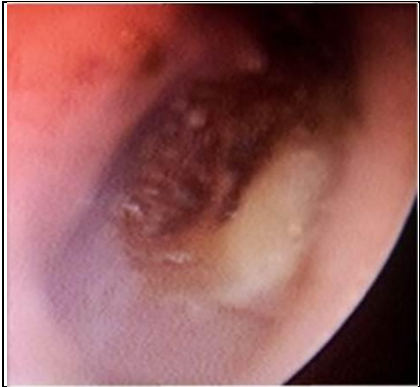Under microscopic visualization the margins of perforation were freshened. The medial and lateral surfaces of the drum in the immediate proximity of the perforations were scratched to encourage the uptake, survival and vascularity of the graft. The middle ear was filled with Gelfoam to stabilize the graft.

Subsequently, the composite graft with its three components was introduced via the external auditory canal. The island of harvested cartilage was placed to close the defect, while two layers of attached perichondrium were allowed to rest on the drum one on each side medially and laterally. The ear canal was packed with Gelfoam soaked in antibiotic ointment. Tragal incision sutured with absorbable stitches. No mastoid bandage was applied.

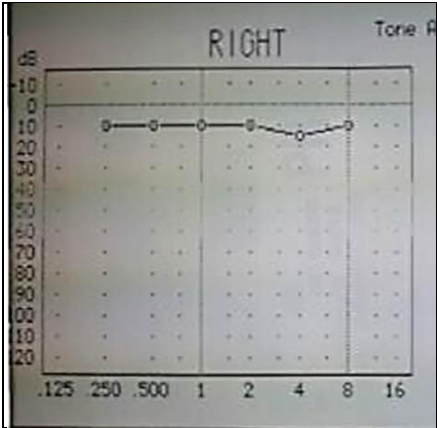
The packing material of Gelfoam and antibiotic ointment was completely suctioned from the external canal 2 weeks after surgical procedure. Gentamycin and Dexamethasone ear drops were used three times a day for a period of additional two weeks. The graft was taken and the perforation sealed, see figure 2.

At six weeks postoperative follow-up, pure tone audiogram was within normal limit with type A tympanogram and the graft was intact and healthy, see figure 3 and 4. There were no episodes of

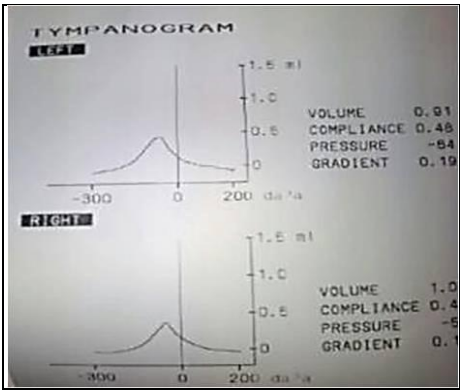
further ear discharge or ear pain during 6 months of follow-up, following which the patient was discharged from our service.



**Figure 2: Healed Graft Two Weeks Post-Operatively**



**Figure 3: Pure Tone Audiogram Six Weeks Post-Operatively**



**Figure 4: Tympanogram Six Weeks Post-Operatively**

**DISCUSSION**

The first published attempt to close the tympanic membrane perforation was in 1640 utilizing an inverted small ivory tube covered with pig's bladder as a lateral graft by Marcus Banzer<sup>3</sup>. In 1960 Heerman reported successful myringoplasty results using autologous temporalis fascia 'onlay' grafts and successful results were also reported using tragal perichondrium<sup>3</sup>.

Subsequently and over the last 40 years, cartilage tympanic membrane reconstruction gained more popularity<sup>16</sup>. Temporalis fascia has been known to be the most widely accepted graft material probably because of its availability through postaural/endaural incision; it was superseded by the cartilage when used as a graft material<sup>3,17</sup>. It can be used as full thickness or in plates of different sizes and shapes. It is well-tolerated by the middle ear; it has long-term survival because it is nourished largely by diffusion and it maintains its rigidity and resists reabsorption and retraction even in severe eustachian tube dysfunction<sup>18</sup>. In some instances, cartilage tympanoplasty is privileged with unbeatable success rates as high as 100%<sup>19</sup>.

It is stated in the literature clearly that auricular cartilages were employed in tympanic membrane grafting via namely four known techniques. The first one is the Inlay Butterfly technique whereby a circumferentially grooved cartilage is squeezed through a small perforation. In the second, a tragal cartilage with an intact one sided perichondrial flap is used as a grafting material via underlay technique and is called the "Perichondrium-cartilage island flap". A third modality is called "Palisade technique" in which strips or slices of bare tragal or cymbal cartilage are pieced together medial to the malleus to seal off the perforation. Last but not least, the "Cartilage shield" in which round piece of conchal cartilage is harvested and the perichondrium on both sides is removed. A small wedge of cartilage is removed to accommodate the handle of the malleus. The graft is then placed medial to the malleus and the remnants of the tympanic membrane<sup>3</sup>.

Our proposed method of composite cartilage grafting is different from previous techniques, though it bears some similarity with the butterfly technique. The stability of the graft material is achieved via the attached perichondrial flaps draping on both tympanic surfaces rather than depending on the groove in the cartilage which might be prove technically more challenging and can be traumatic to the drum remnant during placement.

We believe that our technique is best suited for small to moderate size dry central perforation without middle ear disease. The size of the canal might be a limiting factor as it mandates to have the same basic skills needed to perform paper myringoplasty to great extent. The advantage of this technique is cosmetically small incision on postero-medial aspect of tragus, which could be done under local anesthesia in office setting and to patients unsuitable for general anesthesia due to co-morbid conditions or old age groups. The actual surgical time is shorter than any of other methods of tympanoplasty as it does not involve elevation of tympanomeatal flap nor it requires post aural incision. Success rate and audiometric result is similar to underlay tympanoplasty. However, it might imply surgical technicality for surgeons not familiar with the routine technique of tragal cartilage tympanoplasty.

Tragal cartilage is ideal because it is thin, flat, and sufficient for reconstruction of entire tympanic membrane and it can be used in transcanal procedure. Graft cartilage is known to soften with time, but the matrix of the cartilage remains intact with empty lacunae,

demonstrating degeneration of the chondrocytes. The perceived disadvantage of the cartilage graft is that it creates an opaque tympanic membrane, which could potentially hide pathology inside tympanic cavity<sup>14</sup>.

## CONCLUSION

**Although temporalis fascia grafting is more commonly employed in tympanoplasty, cartilage grafting should be considered as simple, easy and reliable technique of reconstructing the tympanic membrane. Method of cartilage grafting can be tailored according to pathology of the tympanic membrane and middle ear.**

**In our case we report new not previously reported technique which was utilized successfully in tympanic membrane reconstruction. However, consistent and long-term results of this technique are yet to be tested by a prospective study.**

---

**Author contribution:** All authors share equal effort contribution towards (1) substantial contribution to conception and design, acquisition, analysis and interpretation of data; (2) drafting the article and revising it critically for important intellectual content; and (3) final approval of manuscript version to be published. Yes.

**Potential conflicts of interest:** None.

**Competing interest:** None.   **Sponsorship:** None.

**Submission date:** 17 August 2013.   **Acceptance date:** 20 November 2013.

**Ethical approval:** Department of ENT, BDF Hospital, Kingdom of Bahrain.

## REFERENCES

1. Anisur Rahman. Healing of Tympanic Membrane Perforation: An Experimental Study. Available at: <http://diss.kib.ki.se/2007/978-91-7357-243-9/thesis.pdf>. Accessed on 2.9.2013.
2. Rizer FM. Overlay versus Underlay Tympanoplasty. Part I: Historical Review of the Literature. *Laryngoscope* 1997; 107(12 Pt 2): 1-25.
3. Vaidya S, Sharma H. Cartilage Tympanoplasty for Management of TM Perforation: Review of Literature. Available at: <http://www.waent.org/archives/2012/Vol5-1/20120120-cartilage-tympanoplasty/type-1-tympanoplasy.htm>. Accessed on 29.8.2013.
4. Goodhill V. Articulated Polyethylene Prosthesis with Perichondrial Graft in Stapedectomy. *Rev Laryngol Otol Rhinol (Bord)* 1961; 82: 305-20.
5. Linde RE. The cartilage-perichondrium Graft in the Treatment of Posterior Tympanic Membrane Retraction Pockets. *Laryngoscope* 1973; 83(5): 747-53.
6. Tabb HG. Closure of Perforations of the Tympanic Membrane by Vein Grafts: A Preliminary Report of Twenty Cases. *Laryngoscope* 1960; 70: 271-286.

7. Yetiser S, Tosun F, Satar B, et al. Revision Myringoplasty with Solvent-dehydrated Human Dura Mater (Tutoplast): Otolaryngol Head Neck Surg 2001; 124(5): 518-21.
8. Heermann J Jr, Heermann H, Kopstein E. Fascia and Cartilage Palisade Tympanoplasty. Arch Otolaryngol 1970; 91(3): 228-41.
9. Couloigner V, Baculard F, El Bakkouri W, et al. Inlay Butterfly Cartilage Tympanoplasty in Children. Otol Neurotol 2005; 26(2): 247-51.
10. Gerber MJ, Mason JC, Lambert PR. Hearing Results after Primary Cartilage Tympanoplasty. Laryngoscope 2000; 110(12): 1994-9.
11. Adkins WY. Composite Autograft for Tympanoplasty and Tympanomastoid Surgery. Laryngoscope 1990; 100(3): 244-7.
12. Yung M. Cartilage Tympanoplasty: Literature Review. J Laryngol Otol 2008; 122(7): 663-72.
13. Ayache D, Zaki Z, Wiener V, et al. Delayed Luxation of the Stapes into the Vestibule after Cartilage Tympanoplasty. Otol Neurotol 2006; 27(6): 901-2.
14. Ghanem MA, Monroy A, Alizadeh FS, et al. Butterfly Cartilage Graft Inlay Tympanoplasty for Large Perforations. Laryngoscope 2006; 116(10): 1813-16.
15. Dornhoffer JL. Hearing Results with Cartilage Tympanoplasty. Laryngoscope 1997; 107(8): 1094-9.
16. Kerr AG, Byrne JE, Smyth GD. Cartilage Homografts in the Middle Ear: A Long-term Histologic Study. J Laryngol Otol 1973; 87(12): 1193-99.
17. Yu L, Han C, Yu H, et al. Auricular Cartilage Palisade Technique for Repairing Tympanic Membrane Perforation. Zhonghua Er Bi Yan Hou Ke Za Zhi 2001; 36(3): 166-8.
18. Tos M. Cartilage Tympanoplasty: Classifications of Methods-Techniques-Results. Edition I, Germany: Thieme, 2009; 1-432.
19. Neumann A, Kevenhoerster K, Gostian AO. Long-term Results of Palisade Cartilage Tympanoplasty. Otol Neurotol 2010; 31(6): 936-9.