

The Relationship Between *Heart and Neural Crest Derivatives Expressed 2 (HAND2)* and Progesterone Levels with Endometrial Sonography Morphology During Ovarian Stimulation with Clomiphene Citrate

Ganesha Pratama Biyang^{*,**}, Ashon Sa'adi^{*,**}, Samsulhadi^{*}, Rizani Amran^{***}, Relly Yanuari Primariawan^{*,**}, Jimmy Yanuar Annas^{*,**}, Budi Utomo^{****}

ABSTRACT

Background: Pregnancy success is highly determined by embryo dynamics and endometrial receptivity. The detection of biomarkers to assess endometrial receptivity is a promising approach that aids in infertility management. Heart and neural crest derivatives expressed 2 (HAND2) is a progesterone-dependent protein in uterine stromal tissue that triggers cellular changes supporting the formation of a receptive endometrium. HAND2 has potential as a biomarker for assessing endometrial receptivity.

Materials and Methods: In this pre-experimental study, we evaluated endometrial morphology using sonography and measured serum levels of progesterone and HAND2 in the pre-and post-ovulatory phases in 40 patients who underwent ovarian stimulation with 50 mg of clomiphene citrate. The endometrial morphology evaluated included endometrial thickness, echogenic patterns, and periendometrial vascular distribution.

Discussion: Serum levels of progesterone and HAND2 increased in conjunction with morphological changes observed in endometrial sonography. There was a significant correlation between changes in progesterone and HAND2 levels in the pre-and post-ovulatory phases with changes in endometrial sonography.

Conclusion: There is a significant correlation between changes in progesterone and HAND2 levels and changes in endometrial sonography morphology.

Keywords: Endometrium, Progesterone, HAND2, Sonography.

INTRODUCTION

The success of pregnancy is significantly determined by the embryo and the endometrium. A healthy embryo without a receptive endometrium increases the risk of implantation failure. The failure of the endometrium to prepare adequately can reduce pregnancy success rates by up to 49.5%.^{1,2}

Detecting biomarkers to assess endometrial receptivity is an intriguing and helpful approach in infertility management. Clinically, endometrial receptivity can be evaluated through sonographic imaging, biochemical assessments, genetic testing, and other aspects. To date, transvaginal ultrasonography is the most widely used non-invasive method in clinical practice for assessing endometrial receptivity. However, sonographic evaluations are influenced by many factors, including the examiner's subjectivity and variations in ultrasound machines, which leads to inconsistent conclusions regarding the use of sonography in evaluating endometrial receptivity.³

Heart and neural crest derivatives expressed 2 (HAND2) is a protein encoded by the HAND2 gene in humans. The induction of HAND2, which is progesterone-dependent in uterine stromal tissue, triggers cellular changes that support the formation of an endometrium optimal for embryo implantation.⁴

With the advancement of biomarkers in the process of decidualization, research on HAND2 in serum, combined with endometrial morphology assessments using sonography, is considered highly promising. This is particularly significant as it has not been conducted in humans before, is less invasive, and adds value in explaining the pathogenesis of endometrial receptivity.

MATERIALS AND METHODS

The design of this study is a pre-experimental study conducted at Dr. Soetomo General Academic Hospital and Poskesdim Clinic in Bangkalan, East Java. Ethical clearance was approved by the Ethics Committee of Dr. Soetomo General Academic Hospital. A total of 40 patients were recruited for this study. The recruited patients were those who received a dose of 50 mg of clomiphene citrate for ovarian stimulation due to primary or secondary infertility, had regular menstrual cycles, and had a normal body mass index. Patients with a history of hormonal drug use, a history of endometrial surgery such as curettage or hysteroscopy, myomectomy, as well as patients with pathological lesions on the endometrium or those that destroy the endometrium, were excluded from this study.

Samples receiving clomiphene citrate as ovarian stimulation at a dose of 50 mg for 5 days during the early menstrual phase underwent

* Division of Fertility Endocrinology and Reproduction, Department of Obstetrics and Gynecology, Faculty of Medicine, Universitas Airlangga, Surabaya, Indonesia

E-mail: rumahku324@yahoo.co.id

** General Academic Hospital, Surabaya, Indonesia

*** Division of Fertility Endocrinology and Reproduction, Department of Obstetrics and Gynecology, Faculty of Medicine, Universitas Sriwijaya, Palembang, Indonesia

**** Department of Public Health and Preventive Medicine, Faculty of Medicine, Universitas Airlangga, Surabaya, Indonesia

transvaginal sonography on day 12 as the pre-ovulatory phase to evaluate endometrial morphology. The parameters evaluated in sonography included endometrial thickness, endometrial echogenic patterns, and vascular distribution in the endometrial area. The results obtained were then categorized and scored according to Applebaum's criteria. On the same day, blood samples were collected to measure serum progesterone and HAND2 levels using the ELISA method. Similar evaluations were performed on the same patients on days 19-21 as the post-ovulatory phase.

Data were then analyzed using SPSS statistical software with the Spearman test, and the significance level was set at $p < 0.05$.

RESULTS

Patient Characteristics are presented in Table 1.

Table 1. Characteristics of Study Subjects.

Variable	Mean Value \pm SD
Age (years)	27.32 \pm 4.49
Duration of marriage (years)	3.25 \pm 1.41
Body mass index (kg/m ²)	22.66 \pm 1.98
Menstrual cycle (days)	30 \pm 1.86

The results of endometrial sonography morphology are displayed in Table 2, where the echogenic patterns of the endometrium are categorized into groups A, B, and C, and the perimetrial vascular distribution is categorized into groups I, II, and III. Each category was then scored according to Applebaum's criteria. A total score of <6 indicates a non-receptive endometrium, while a score ≥ 6 indicates a receptive endometrium.

Table 2. Characteristics of Transvaginal Sonography Examination Results.

Variable	Variable Category	Pre-ovulation	Post-ovulation
Endometrial thickness (mm)			6.80 \pm 1.27
Endometrial pattern (n)	A	7 (17.5%)	4 (10%)
	B	12 (30%)	10 (25%)
	C	21 (52.5%)	26 (65%)
Subendometrial blood flow distribution (n)	I	0	21 (52.5%)
	II	28 (70%)	19 (47.5%)
	III	12 (30%)	0
Total score		3.30 \pm 2.61	6.67 \pm 2.65

The examination revealed a significant increase in HAND2 levels in the pre-and post-ovulation phases with $p = 0.000$ (Figure 1). Additionally, there was a significant correlation between changes in serum progesterone and HAND2 levels in the pre-and post-ovulation phases with changes in endometrial sonography morphology (Table 3).

Table 3. Correlation of Changes in Progesterone and HAND2 Levels with Total Ultrasound Score.

Variable	Pre-ovulation	Post-ovulation	p-value
Progesterone (ng/mL)	0.58 \pm 0.52	8.59 \pm 6.31	0.009
HAND2 (ng/mL)	7.51 \pm 2.69	11.58 \pm 5.48	0.000

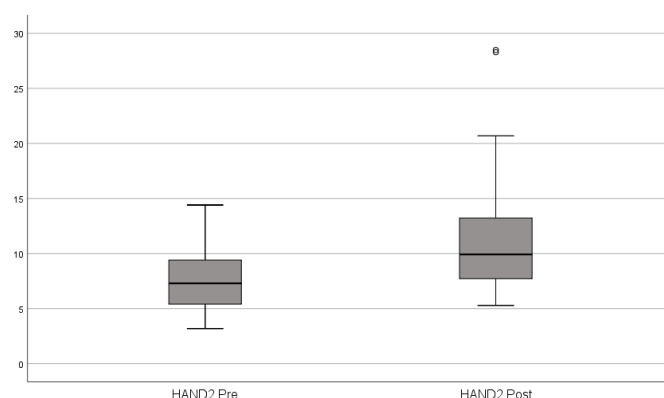


Figure 1. Comparison of HAND2 Levels Pre-ovulation and Post-ovulation.

DISCUSSION

The endometrium is a highly dynamic tissue that undergoes cyclical changes in response to steroid hormones to create a receptive window for implantation. These cyclical changes are reflected in the ultrasonographic appearance of the endometrium. Various factors, such as unexplained infertility, can lead to lower pregnancy rates after ovarian stimulation with clomiphene citrate. However, it should be noted that the anti-estrogenic effect of clomiphene citrate on the endometrium may cause disturbances during implantation. This effect is dose-dependent, and higher doses exacerbate this issue.^{2,6}

A meta-analysis by Gadalla reported that using 50 mg of clomiphene citrate resulted in an endometrial thickness reduction of 0.5-2.3 mm compared to non-use.⁶ Another study by Elkattan found that pre-ovulatory endometrial thickness with ovulation induction using clomiphene citrate was 8.87 \pm 2.5 mm with a type C echogenic pattern.⁷ Other studies comparing the effects of clomiphene citrate on endometrial morphology during the proliferative and mid-secretory phases reported similar results, with endometrial thicknesses of 9.7 \pm 2.05 mm and 10.7 \pm 3.06 mm, respectively. This study also revealed that the majority of endometrial echogenic patterns observed were of type C. Furthermore, this study compared progesterone levels in both phases, with pre-ovulatory progesterone levels of 0.54 \pm 0.36 ng/mL and mid-secretory phase levels of 9.76 \pm 4.47 ng/mL.^{8,9}

After ovulation, progesterone levels increase. Progesterone, along with proteins regulated by progesterone and/or cyclic adenosine monophosphate (cAMP), including HAND2, FOXO1, HOXA-10, and STAT, forms a crucial network for the decidualization of human endometrial stromal cells. Decidualization involves morphological and functional differentiation, as well as the expression of specific decidual factors and markers such as prolactin and IGFBP-1. In the secretory phase, the endometrium becomes hyperechoic due to the accumulation of secretory products such as glandular mucus, glycoproteins, and lectins. This is consistent with our study, where the mean serum progesterone level in the luteal phase increased to 8.59 \pm 6.31 ng/mL. The sonographic evaluation showed endometrial thickness of 9.12 \pm 1.80 mm with a hyperechoic (type C) echogenic pattern and type I vascular distribution, evenly distributed in the endometrium and subendometrial areas.^{10,11}

In our study, a positive correlation was found between changes in pre- and post-ovulatory progesterone levels and changes in pre- and post-ovulatory HAND2 levels with $p = 0.000$. This is consistent with previous studies on animal models, which revealed a positive correlation between progesterone expression and HAND2 expression. A study by Šučurović suggested that progesterone acts as a regulator of HAND2 expression, and the accumulation of both (HAND2/PR2) in the endometrium creates a microenvironment conducive to embryo attachment and implantation.¹²

In our study, HAND2 levels were measured twice, in the pre-ovulatory and post-ovulatory stages. This study showed an increase in mean HAND2 levels from 7.51 ± 2.69 ng/mL in the pre-ovulatory phase to 11.58 ± 5.48 ng/mL in the post-ovulatory phase. These results align with the study by Ramathal et al., which suggested a possible shift in the regulatory pathway between progesterone and cAMP through the HAND2 pathway during the decidualization of the human extracellular matrix.¹³

CONCLUSION

This study **demonstrates** a significant correlation between changes in progesterone and HAND2 levels and alterations in endometrial sonography morphology. Future studies should evaluate other biomarkers such as estradiol levels and folliculometry to gain a more comprehensive understanding of the dynamics and relationships between variables.

Authorship Contribution: All authors share equal effort contribution towards (1) substantial contributions to conception and design, acquisition, analysis and interpretation of data; (2) drafting the article and revising it critically for important intellectual content; and (3) final approval of the manuscript version to be published. Yes

Acknowledgments: Acknowledgments are extended to the Outpatient Clinic of the Obstetrics and Gynecology Department at Dr. Soetomo General Academic Hospital, Surabaya, and Poskesdim Clinic in Bangkalan.

Conflict of Interest: The authors declare that they have no conflicts of interest to disclose.

Funding: This research was self-funded by the authors, with no support from sponsors or scholarships.

Ethical Considerations: This study received ethical approval from the Ethics Committee of Dr. Soetomo General Academic Hospital aboard 0965/KEPK/IV/2024.

Acceptance Date: 30-10-2024

REFERENCE

1. Bhurke AS, Bagchi IC, Bagchi MK. Progesterone-regulated endometrial factors controlling Implantation. *Am J Reprod Immunol.* 2016;75(3):237-45. doi: 10.1111/aji.12473.
2. Zhang CH, Chen C, Wang JR, Wang Y, Wen SX, Cao YP, Qian WP. An endometrial receptivity scoring system basing on the endometrial thickness, volume, echo, peristalsis, and blood flow evaluated by ultrasonography. *Front Endocrinol (Lausanne).* 2022;13:907874. doi: 10.3389/fendo.2022.907874.
3. Jiao Y, Xue N, Shui X, Yu C, Hu C. Application of ultrasound multimodal score in the assessment of endometrial receptivity in patients with artificial abortion. *Insights Imaging.* 2020;11(1):29. doi: 10.1186/s13244-020-0840-5.
4. Murata H, Tsuzuki T, Kido T, Kakita-Kobayashi M, Kida N, Hisamatsu Y, Okada H. Progesterone-induced heart and neural crest derivatives-expressed transcript 2 inhibits angiopoietin 2 via fibroblast growth factor 9 in human endometrial stromal cells. *Reprod Biol.* 2019;19(1):14-21. doi: 10.1016/j.repbio.2019.02.005.
5. Applebaum M. The uterine biophysical profile. *Ultrasound Obstet Gynecol* 1995;5:67-8.
6. Gadalla MA, Huang S, Wang R, Norman RJ, Abdullah SA, El Saman AM, Ismail AM, van Wely M, Mol BWJ. Effect of clomiphene citrate on endometrial thickness, ovulation, pregnancy and live birth in anovulatory women: systematic review and meta-analysis. *Ultrasound Obstet Gynecol.* 2018;51(1):64-76. doi: 10.1002/uog.18933.
7. Elkattan. Ultrasonographic markers of endometrial receptivity of letrozole and clomiphene citrate in unexplained infertile women. *Middle East Fertility Society Journal.* 2013;18(2):84-88. <https://doi.org/10.1016/j.mefs.2012.07.008>.
8. Dehbashi M, Parsanezhad E, Alborzi S, Zarei A. Effect of clomiphene citrate on endometrium thickness and echogenic patterns. *International Journal of Gynecology & Obstetrics.* 2003;80(1):49-53. [https://doi.org/10.1016/S0020-7292\(02\)00341-7](https://doi.org/10.1016/S0020-7292(02)00341-7).
9. Corbacioglu A, Baysal B. Effects of steroid hormone levels on the ultrasound appearance of the preovulatory endometrium in controlled ovarian hyperstimulation cycles. *Int J Fertil Steril.* 2012;5(4):203-6.
10. Murata H, Tsuzuki T, Kido T, Kakita-Kobayashi M, Kida N, Hisamatsu Y, Okada H. Progesterone-induced heart and neural crest derivatives-expressed transcript 2 inhibits angiopoietin 2 via fibroblast growth factor 9 in human endometrial stromal cells. *Reprod Biol.* 2019;19(1):14-21. doi: 10.1016/j.repbio.2019.02.005.
11. Murata H, Tanaka S, Tsuzuki-Nakao T, Kido T, Kakita-Kobayashi M, Kida N, Hisamatsu Y, Tsubokura H, Hashimoto Y, Kitada M, Okada H. The transcription factor HAND2 up-regulates transcription of the IL15 gene in human endometrial stromal cells. *J Biol Chem.* 2020;295(28):9596-9605. doi: 10.1074/jbc.RA120.012753.
12. Šučurović S, Nikolić T, Brosens JJ, Mulac-Jeričević B. Analysis of heart and neural crest derivatives-expressed protein 2 (HAND2)-progesterone interactions in peri-implantation endometrium. *Biol Reprod.* 2020;102(5):1111-1121. doi: 10.1093/biolre/iaaa013.
13. Ramathal CY, Bagchi IC, Taylor RN, Bagchi MK. Endometrial decidualization: of mice and men. *Semin Reprod Med.* 2010;28(1):17-26. doi: 10.1055/s-0029-1242989.