

# A Unique Journey: Navigating Pregnancy with Situs Inversus Totalis, AVSD, and Transposition of The Great Arteries (TGA): A Rare Case of Safe Maternal and Fetal Outcome

Yuliaty Eleanor Ponga<sup>\*,\*\*\*</sup>, Nareswari Imanadha Cininta M<sup>\*\*,\*\*</sup>, Manggala Pasca Wardhana<sup>\*\*,\*\*</sup>, Hermanto Tri Joewono<sup>\*\*,\*\*</sup>, Agus Sulistiyono<sup>\*\*,\*\*</sup>

## ABSTRACT

**Situs inversus is characterized by a mirrored placement of the thoracic and abdominal organs, opposite to their typical placement seen in situs solitus. With a prevalence of only 1 in 10,000, this condition is exceptionally rare. The defining feature of situs inversus totalis is the heart's placement on the right side of the chest, a condition termed dextrocardia. Most cases present with no complications or symptoms, but situs inversus totalis has a 2-5% prevalence of congenital heart disease, with transposition of the great arteries being the most frequent condition. This case involved a 31-year-old woman with situs inversus totalis, AVSD, and malposed great arteries who was pregnant. During the pregnancy, the patient was hospitalized once at 27/28 weeks of gestation due to dyspnea and was diagnosed with cardiomegaly and lung inflammation. She was hospitalized for one month and discharged in good condition. The pregnancy continued until 34 weeks of gestation, at which point it was terminated via cesarean section. Both the mother and the baby were discharged from the hospital with no complaints.**

**Keywords:** situs inversus, dextrocardia, pregnancy.

## CASE DESCRIPTION

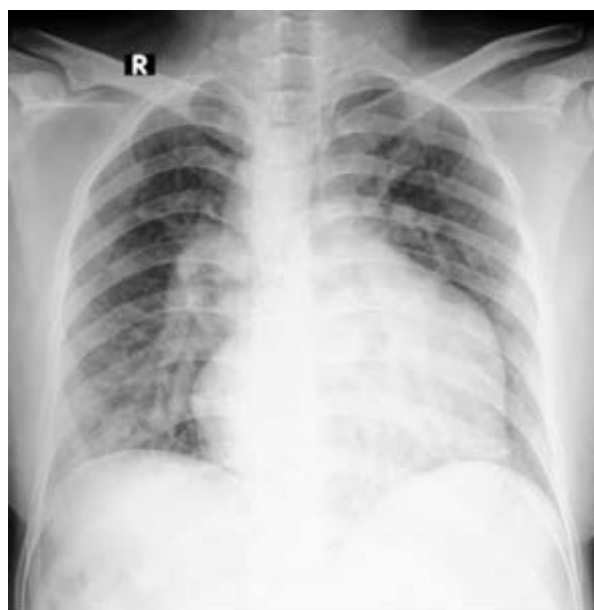A 31-year-old primigravida patient, referred from Sosodoro Hospital, Bojonegoro, presented to the Obstetric outpatient clinic at Dr. Soetomo General Academic Hospital with a primigravida at 11/12 weeks, DORV, VSD, Overriding Aorta, Pulmonary Stenosis, severe MR, and a large ASD with an L to R shunt. There were no indications of cardiopulmonary issues in the patient. We consulted the cardiology outpatient clinic, and the echocardiography results revealed that the patient had situs inversus, an intermediate Atrioventricular Septal Defect, malposed great arteries, a right aortic arch, severe valvular pulmonary stenosis, trivial MR, and an imbalanced ventricle (mWHO class III), with a high maternal mortality and morbidity risk of 19-27%.

Due to the patient's gravidity with situs inversus, AVSD, and malposed great arteries, we held a conference with the cardiology and anesthesiology teams. The outcome was that the pregnancy could continue until 34 weeks with strict monitoring. Echocardiography was to be performed every trimester, and the patient was to be monitored closely for signs of arrhythmia and heart failure. Given the mWHO class III status, delivery was recommended via painless labor or cesarean section.

On February 22, 2024, a fetomaternal ultrasound was performed, which revealed fetal biometrics of ~ 26/27 weeks, Doppler velocimetry within normal limits, and fetal echocardiography also within normal limits.

At 27/28 weeks of pregnancy, the patient complained of dyspnea for three days before being admitted to the hospital. Upon examination, the patient remained conscious and displayed clear orientation regarding person, place, and time. She appeared non-pale during the general examination, with a blood pressure of 111/62 mmHg and a steady pulse

of 98 bpm. She had a normal jugular venous pressure, a respiratory rate between 22 and 24 breaths per minute, and no indications of clubbing or cyanosis. No evidence of congestive heart failure was detected. Upon cardiovascular assessment, the apex was positioned in the right 6th intercostal space, a grade 2/6 systolic murmur was heard along the right parasternal border, and rhonchi were heard in dextra hemithorax.

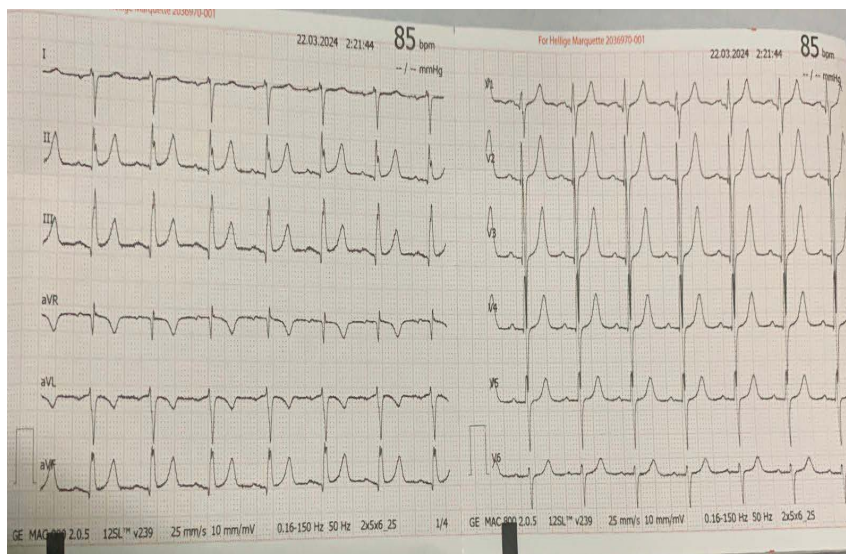


**Figure 1.** A chest X-ray revealed dextrocardia with cardiomegaly and lung inflammation.

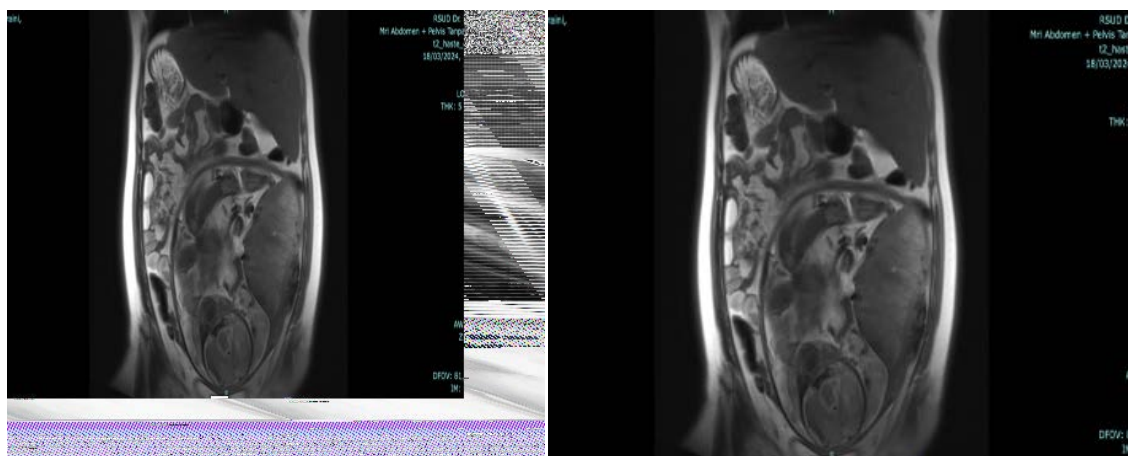
\* Maternal-Fetal Medicine Trainee, Department of Obstetrics and Gynecology, Dr. Soetomo General Academic Hospital, Surabaya, Indonesia. E-mail: yeponga@gmail.com

\*\* Sub-Division Of Obsetrics and Gynecology, Maternal- Fetal Medicine, Dr. Soetomo General Academic Hospital, Surabaya, Indonesia.

\*\*\* Faculty of Medicine, Airlangga University, Surabaya, Indonesia.



**Figure 2.** The ECG shows a sinus rhythm at 85 bpm, with signs suggestive of left ventricular hypertrophy (LVH) as indicated by tall R waves in precordial leads, there are also T-wave and ST-segment abnormalities.



**A**

**B**

**Figure 3a-3b.** MRI results: Situs inversus, with the liver, gallbladder, and hepatic flexure positioned in the sinistral region, while the spleen, stomach, small bowel, splenic flexure, descending colon, and sigmoid colon positioned in the dextral region, and the transverse colon occupying the superior quadrant. Left hydronephrosis grade II was also observed. The fetus was single and intrauterine.

Echocardiography results: Situs Inversus, intermediate AVSD (hypoplastic RV with imbalanced ventricles), severe subvalvular and valvular PS (PG 102 mmHg), malposed great arteries, severe TR, and a right aortic arch.

The patient was administered intravenous ampicillin-sulbactam at dosage 1,5 gram four times daily for five days and propranolol 10 mg three times daily, and continuous fetal monitoring. After spending a month in the hospital, the patient was discharged with no cardiopulmonary or obstetric complaints.

At 34 weeks gestation, a cesarean section and sterilization were conducted to terminate the pregnancy. The baby was born male, weighing 2200 grams, with an Apgar score of 8-9. Gestational age was 35 weeks, with LS between p25 and 50.

Four days after the cesarean section, the patient and baby were discharged from Dr Soetomo General Academic Hospital with no complaints.

## DISCUSSION

Situs inversus presents as a mirror version of situs solitus. Contrary to popular belief, it occurs more frequently and is defined by the reversed positioning of the heart and internal organs in relation to situs solitus.<sup>1</sup> Aristotle (384–322 BC) first documented this anomaly in animals, while Fabricius provided the earliest human observations in the 1600s, describing a reversed liver, and in 1643, Marco and Severino were the first to identify dextrocardia.<sup>1</sup> Despite the external bilateral symmetry observed in humans and all vertebrates, their internal organs are asymmetrically arranged. Most visceral organs differ in both position and structure along the left-right (LR) axis. The standard configuration of these organs is termed situs solitus, while any deviation from this pattern is classified as a laterality disorder.<sup>2</sup> When all organs in the thoracic and abdominal cavities are completely reversed from their normal positions, the condition is called situs inversus totalis. Situated between situs solitus (normal anatomy) and situs inversus totalis (complete reversal) is situs ambiguus, characterized by an intermediate organ arrangement. According to Aylsworth, this condition involves isomerism, heterotaxy, and multiple structural abnormalities affecting

various abdominal or thoracic organs.<sup>3</sup> In contrast, Kosaki et al. describe situs ambiguus as situation in which the body's left-right axis does not follow a normal or fully reversed pattern.<sup>4</sup> Their approach may be the most practical: classifying normal anatomy as situs solitus, complete organ reversal as situs inversus, and any other left-right developmental abnormality as situs ambiguus.<sup>4</sup>

Dextrocardia with situs inversus typically does not cause symptoms and often goes undetected unless it is incidentally discovered during medical examinations for unrelated health conditions.<sup>4</sup> Among those with situs inversus, congenital heart disease is found in 2% to 5% of cases, the typical congenital heart defect found in patients with situs inversus and dextrocardia is discordant atrioventricular (AV) connection in 44% and discordant ventriculo-atrial (VA) connection in 30%.<sup>5</sup> Transposition of the great vessels (TGA) being the commonly anomaly in Dextrocardia with situs inversus.<sup>6</sup> TGA is a congenital heart anomaly that occurs in fewer than 1% of all congenital heart disease cases<sup>7</sup>, but in situs inversus occurrence of TGA is 34 % of patients with congenitally corrected TGA have situs inversus.<sup>8</sup> Certain congenital conditions such as asplenia (right isomerism) and polysplenia (left isomerism) also can occur in dextrocardia with situs inversus.<sup>9</sup> Kartagener's syndrome, characterized by primary ciliary dyskinesia (PCD) that predisposes individuals to lung and sinus infections, is often linked to mirror-image dextrocardia. Around 25% of situs inversus cases associated with PCD exhibit this cardiac abnormality. The condition is characterized by three key symptoms— bronchiectasis, sinusitis, and situs inversus.<sup>10</sup>

This patient did not present with cyanosis or sinusitis but was hospitalized twice—once due to dyspnea because of lung inflammation and later for delivery.

Situs inversus is diagnosed using a combination of physical examination, chest X-ray, echocardiography, and MRI. These diagnostic imaging tools are essential for locating the aorta relative to the midline, the blood vessels, spleen, kidneys, gallbladder, liver, and stomach, as well as internal organs, including the cardiac apex.<sup>11</sup>

There are only a handful of documented instances of pregnancies occurring in individuals with situs inversus.<sup>12</sup> The prognosis largely depends on structural and functional abnormalities, which are frequently associated with severe congenital defects such as transposition of the great vessels, tricuspid valve atresia, complete atrioventricular septal defect (AVSD), pulmonary artery atresia, and single ventricle.<sup>13-15</sup> Generally individuals with situs inversus and dextrocardia, in the absence of other congenital anomaly have a normal life expectancy and face similar risks of developing acquiring diseases as others in their age and sex group.<sup>16,17</sup> Similarly, isolated dextrocardia during pregnancy does not usually cause complications, nor does pregnancy significantly impact the condition unless other factors are involved. However careful monitoring is advised for babies that are small gestational age.<sup>18</sup>

## CONCLUSION

**Situs inversus is usually diagnosed by coincidence and infrequently observed in the context of pregnancy. The presence of other congenital heart diseases greatly influences the prognosis, as seen in this patient with malposed great arteries and AVSD. In this case, the pregnancy was successful, despite the patient having other congenital heart conditions, due to strict observation and the patient's adherence to medical advice.**

**Acknowledgments:** Thank you Sub-Division Of Obstetric and Gynecology Maternal-fetal Medicine, Dr. Soetomo General Academic Hospital Surabaya, and Faculty of Medicine, Airlangga University,

Surabaya.

**Funding:** There was no specific funding from government, commercial, or non-profit entities for this research.

**Disclosure:** The authors have stated their absence of any conflicts of interest regarding this study.

**Authorship Contribution:** All authors contributed to article preparation and paper revision and have collectively assumed responsibility for all aspects of this work.

**Ethical Consideration:** This case report not require ethical approval because this case report does not involve experimental interventions, is fully anonymized, and includes informed consent from the patient.

**Data Availability:** No datasets were generated or analyzed for this case report. All relevant information is included in the article.

**Potential Conflicts of Interest:** None

**Competing Interest:** None

**Acceptance Date:** 20-02-2025

## REFERENCES

1. Eitler K, Bibok A, Telkes G. Situs Inversus Totalis: A Clinical Review. *Int J Gen Med.* 2022;15:2437-2449. doi: 10.2147/IJGM.S295444.
2. Aylsworth AS. Clinical aspects of defects in the determination of laterality. *Am J Med Genet.* 2001;101(4):345-55.
3. Kosaki K, Casey B. Genetics of human left-right axis malformations. *Semin Cell Dev Biol.* 1998 Feb;9(1):89-99. doi: 10.1006/scdb.1997.0187.
4. Ma N, Jiang SL, Huang LJ, Zhao SH, Xu ZY, Ling J, Zheng H. Diagnosis of isolated dextrocardia using angiocardiography or surgery. *Chin Med J (Engl).* 2004;117(11):1655-8.
5. Maldjian PD, Saric M. Approach to dextrocardia in adults: review. *AJR Am J Roentgenol.* 2007;188(6):S39-49; quiz S35-8. doi: 10.2214/AJR.06.1179.
6. Sohns JM, Steinmetz M, Schneider H, et al. Situs inversus totalis with congenitally corrected transposition of the great arteries: insights from cardiac MRI. *Springerplus.* 2014;3:601. doi: 10.1186/2193-1801-3-60.
7. Ghorbnazadeh A, Zirak N, Fazlinezhad A, Moenipour A, Manshadi HH, Teshnizi MA. Situs Inversus with Levocardia and Congenitally Corrected Transposition of Great Vessels in a 35 year old Male: A Case report. *Electron Physician.* 2017;9(1):3570-3574. doi: 10.19082/3570.
8. Ji YQ, Sun PW, Hu JX. Diagnosis and surgical treatment of congenital dextrocardia. *Di Yi Jun Yi Da Xue Xue Bao.* 2002;22(6):536-8.
9. Bitar FF, Shbaro R, Mroueh S, Yunis K, Obeid M. Dextrocardia and corrected transposition of the great arteries (I,D,D) in a case of Kartagener's syndrome: a unique association. *Clin Cardiol.* 1998;21(4):298-9. doi: 10.1002/clc.4960210414.
10. Pedreira-Garcia WM, Vando-Rivera V, Rodriguez-Martinez M, Velazquez A, De Jesus Ramos C, Otero-Dominguez Y, Rodriguez-Cintron W, Del Olmo-Arroyo F. Situs Inversus Totalis in the Critical Care Unit: A Case Report and Literature Review. *Cureus.* 2023;15(9):e45381. doi: 10.7759/cureus.45381.
11. Fung TY, Chan DL, Leung TN, Leung TY, Lau TK. Dextrocardia in pregnancy: 20 years' experience. *J Reprod Med.* 2006;51(7):573-7.

12. Deepika, Wadhwa L, Shekhar C, Saini J, Chetani M. Successful Obstetric Outcome in Dextrocardia with Situs Inversus and Moderate Pulmonary Hypertension- Rare Case. *J Clin Diagn Res.* 2016 ;10(10):QD08-QD10. doi: 10.7860/JCDR/2016/20429.8749.
13. Abraham B, Shivanna S, Tejesh CA. Dextrocardia and ventricular septal defect with situs inversus: Anesthetic implications and management. *Anesth Essays Res.* 2012;6(2):207-9. doi: 10.4103/0259-1162.108333.
14. Indarini PF. Truncus Arteriosus Type I: A Case Report. *Indonesia Journal of Biomedical Science.* 2016;10(1):5–11. <https://doi.org/10.15562/ijbs.v10i1.23>.
15. Saputra BML, Wibhuti IBR, Suastika LOS, Sari NMAW. The comparison of mitral annular plane systolic excursion (MAPSE) and mitral annular systolic velocity (Sm) in determining subclinical left ventricular systolic dysfunction in patients with type 2 diabetes mellitus. *Indonesia Journal of Biomedical Science.* 2022;16(2):70–77. <https://doi.org/10.15562/ijbs.v16i2.414>.
16. Deshimo G, Abebe H, Damte G, Demeke E, Feleke S. A Case Report of Dextrocardia with Situs Inversus: A Rare Condition and Its Clinical Importance. *Case Rep Med.* 2024;2024:2435938. doi: 10.1155/2024/2435938.
17. Shamsudin SB, Hashim JH, Ismail NNN, Koentjoro MP. Blood Lead Concentrations and The Neuropsychology Scores of Pregnant Women in Klang Valley, Malaysia. *Indonesian Journal of Medical Laboratory Science and Technology.* 2020;2(1):11–20. <https://doi.org/10.33086/ijmlst.v2i1.1499>.
18. Radhika BH, Harshini, Priyanka. Successful pregnancy outcome in a rare case of complete situs inversus in primigravida, a case report. *International Journal of Reproduction, Contraception, Obstetrics and Gynecology.* 2017;4(4):1203–1205. <https://doi.org/10.18203/2320-1770.ijrcog20150457>.