


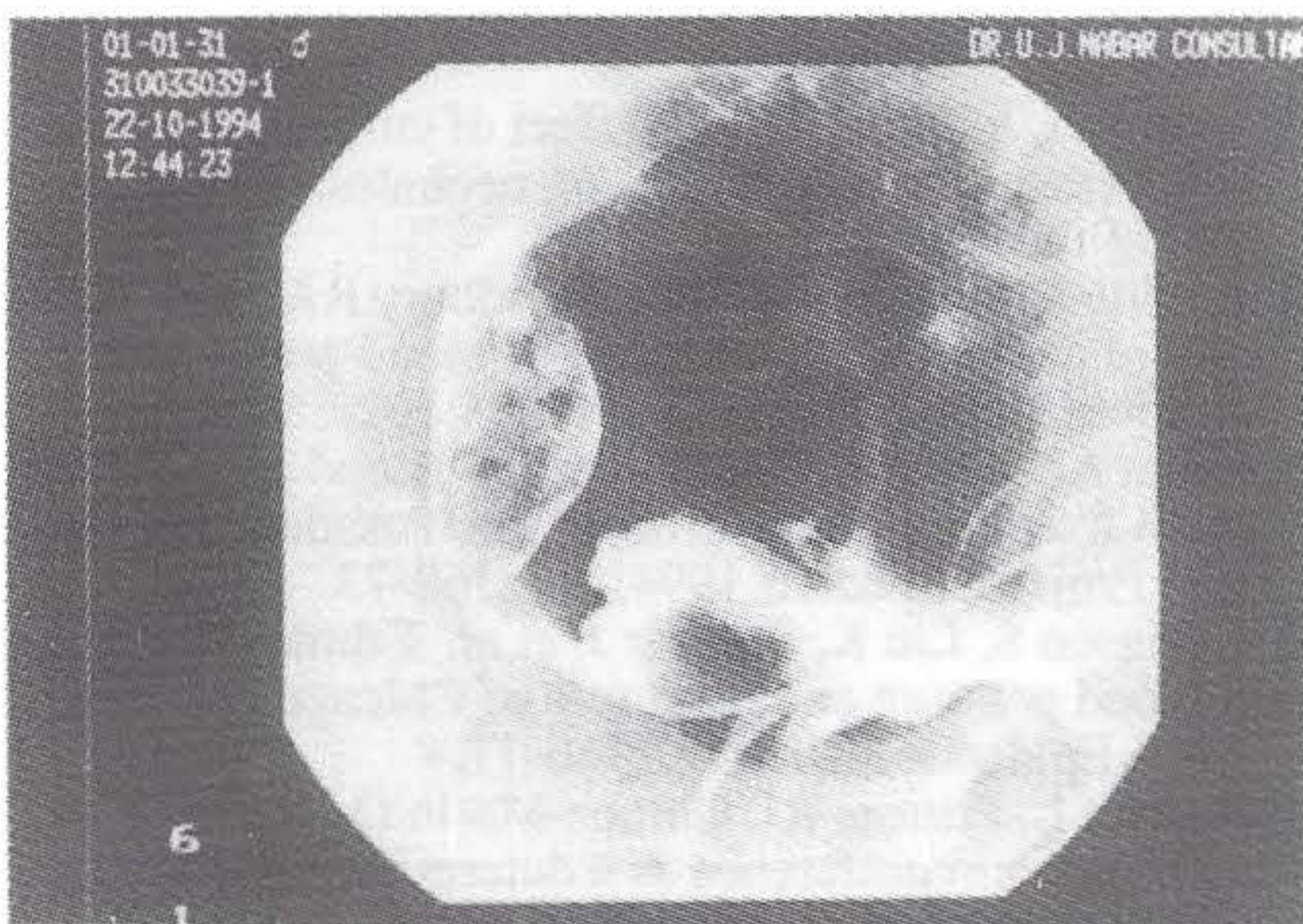
Medical Quiz

Najeeb S Jamsheer, MD
Neelam Malik, MD

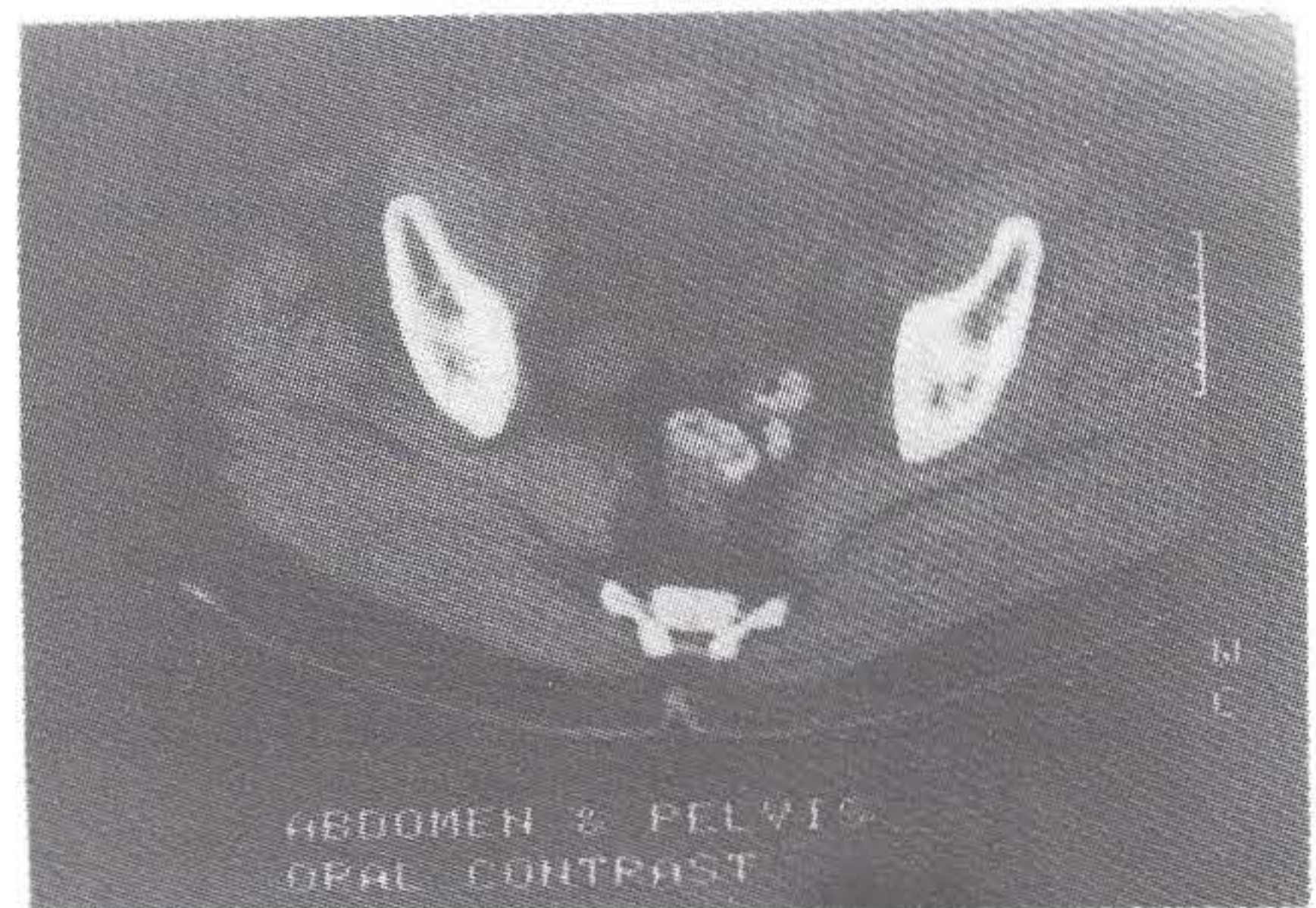
A 63 year old Bahraini male presented with right loin pain and haematuria. Ultrasound (US) examination was performed followed by intravenous urography (IVU). Based on the US, IVU findings and absence of stones on the KUB, a percutaneous nephrostomy was performed followed by antegrade pyelogram through the nephrostomy tube (Fig 1). Retrograde pyelography (Fig 2) and CT of the pelvis (Fig 3) were then carried out to visualise the pelvic ureter and the urinary bladder.



Antegrade pyelography



Retrograde pyelography



CT scan pelvis

1. What are the antegrade pyelography, retrograde pyelography and CT scan abnormal findings ?
2. What is your diagnosis ?

Answers on page 61