

Limited Open Reduction and Percutaneous Screw Fixation of Displaced Intra-Articular Fracture of Calcaneus: Review of 48 Fractures

Tariq El khalifa, MS (Ortho), FRCS Ed* Mohammed El Bagali, CABS**
Waseem Yousif, MBBS*** Feras Hashem, MD****

Objective: To evaluate the result of treating displaced intra-articular fracture of calcaneus using minimal open reduction and percutaneous screw fixation.

Setting: Orthopedic Department, Salmaniya Medical Complex (SMC).

Design: Retrospective study.

Method: A review of 50 patients who had percutaneous screw fixation for displaced intra-articular fracture of calcaneus was done. Soeur and Remy modification of Essex Lopresti for the assessment of the degree of comminution was used. Forty-four patients were evaluated for an average 2.5 years (1 to 4 year) after surgery. The outcome was assessed using the functional hind foot score described by Paley et al and their radiological criteria.

Result: Satisfactory results were obtained in 79% of displaced intra-articular fracture of calcaneus, grade mild to moderate comminution. Only two patients with superficial infection were encountered.

Conclusion: In this study, operable cases of displaced intra-articular fracture of calcaneus, mild to moderate comminution were treated adequately and effectively using percutaneous screw fixation. Percutaneous screw fixation of the displaced intra-articular fracture of the calcaneus is an effective, safe, and reproducible method of treatment.

Bahrain Med Bull 2011; 33(2):

Fracture of the calcaneus constitutes approximately 60% of all tarsal injuries, and represents 2% of body fractures¹. The disabling nature of severe calcaneus fracture and its huge economic burden has long been known and it remains so today^{2,3}. In 2000, Sanders noted, "Although modern operative intervention has improved the outcome in many patients, there still is no real consensus on classification, treatment, operative technique, or postoperative management"⁴.

* Chief Resident Orthopedic Surgery

** Consultant Orthopedic Surgeon

*** Senior Resident Orthopedic Surgery

**** Senior Resident Orthopedic Surgery

Department of Orthopedic

Salmaniya Medical Complex

Kingdom of Bahrain

Email: tmmkh2000@yahoo.com

Since the advance of computer tomography, a better understanding of the comminution of the joint surface and several classifications has been evolved and applied^{1,5,6}. The treatment options vary from non-operative to operative using wide exposure, plate fixation and bone graft. The non-operative treatment has many complications; it includes inability to maintain reduction. Consequently, there will be broadening of heel, muscle imbalance, loss of motion, peroneal impingement, impaired gait, intractable pain, and early development of subtalar arthritis^{7,8}. The operative option improves the results in many fractures; however, it has its own risks. Wide exposure carries the risks of high incidence of wound dehiscence, deep infection, and possible subsequent complications. Plate fixation increases the risk of peroneal impingement, no advantage for early weight bearing. Using bone graft to support the thalamic area has now become questionable and has fallen into disfavor^{9,10,11}.

Following this line of reasoning, limited open reduction and percutaneous screw fixation could be the ideal option for operable displaced intra-articular fracture of calcaneus.

The aim of this study is to evaluate the treatment of displaced intra-articular fracture using limited open reduction and percutaneous screw fixation.

METHOD

A retrospective review of 50 patients who had minimal open reduction and percutaneous screw fixation for displaced intra-articular fracture of calcaneus between January 2006 and May 2009 was done. Six patients were excluded as they failed to complete the minimal follow up period of six months. Therefore, 44 patients with 48 displaced intra-articular fracture of calcaneus, four patients had bilateral fracture calcaneus, were included in the study.

The patients were assessed with plain radiography. The standard three views for calcaneus were performed, lateral, axial, and Broden's views. In addition, antero-posterior view of the foot and the ankle were done to exclude associated fractures. Only displaced intra-articular fracture of the calcaneus was included in the study. The fractures were evaluated for Bohler's angle, Gissane's angle, shape, malalignment, congruity of articular surface and the possibility of incarcerated fragment. The fractures were classified according to Soeur and Remy modification of Essex Lopresti for the assessment of the degree of comminution, which depends on the number of secondary fracture lines that extend anteriorly and posteriorly from the primary fracture line, see figure 1^{12,13}.

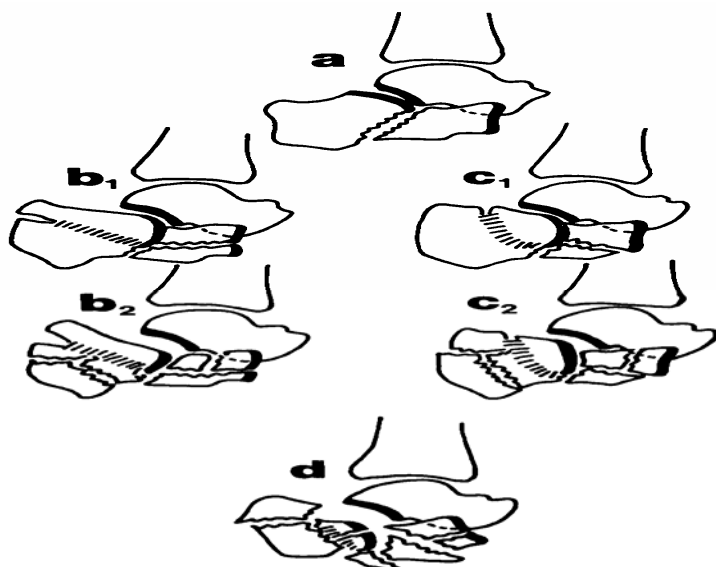


Figure 1(a-d)^{12,13}: a: Two-Part Shear Fracture Type
b₁ and c₁: Mild Comminution
b₂ and c₂: Moderate Comminution
d: Severely Comminuted

Accordingly, the tongue type and central depression type are subdivided into different groups. It is considered mild comminution when there is one anterior and one posterior secondary fracture lines, moderate when there are more than one anterior and posterior secondary fracture lines, and severely comminuted when there are numerous fragments and major displacement. The average interval between admission and operation was three days (1-5 days).

The patient is placed in lateral decubitus position with the affected leg upward, medial reduction to realign other fragments^{7,14}. The tuberosity deformity is corrected by 4 mm shanz screw or 1.8 mm Steinmann pin. The anterior process deformity is corrected with planter flexion of the foot. Short lateral approach to the posterior subtalar joint is implemented. Disimpaction of the medial part and elevation of the lateral part of the facet is achieved using a large hemostat or small bone lever, see figure 2 and 3. The fragment is fixed temporarily by cannulated 3.5 mm screws (figure 4, 5).

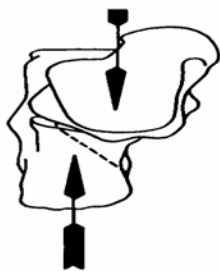


Figure 2(A)



Figure 2(B)

Figure 2 (A, B)^{7,14}: Deformities in Intra-Articular Fracture of Calcaneum

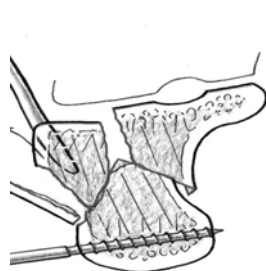


Figure 3(A)

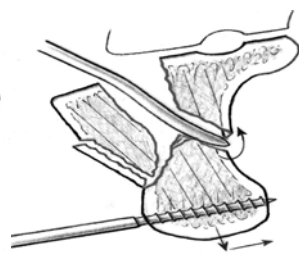


Figure 3(B)

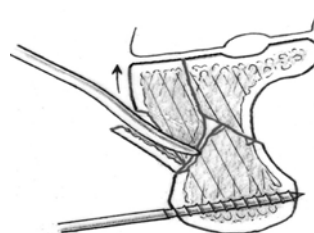


Figure 3 (C)

Figure 3 (A-C)¹⁵: Medial Reduction and Realignment of the Other Fragments

A: Reduction of the Tuberosity Using Schanz screw

B: Reduction of the Tuberosity to the Anteromedial Fragment

C: Elevation of the Lateral Part of the Posterior Facet

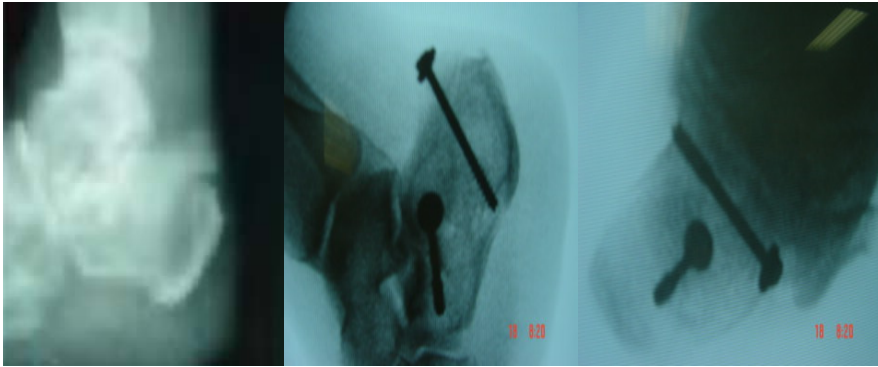


Figure 4(A)

Figure 4(B)

Figure 4(C)

Figure 4 (A-C): A: Tongue Type (b₂) B and C: Fixed Percutaneously

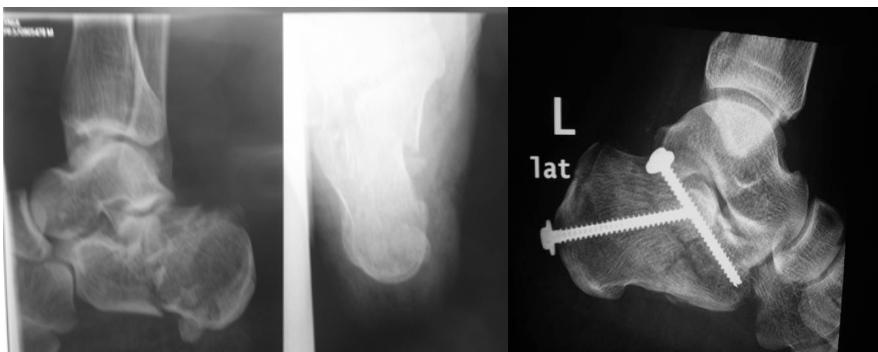


Figure 5(A)

Figure 5(B)

Figure 5(C)

Figure 5 (A-C): A and B: Joint Depression Type (c₂), C: Fixed Percutaneously

Reduction is considered accepted when there is adequate medial alignment seen in axial view, Bohler's angle is $30^{\circ} \pm 5^{\circ}$ in lateral view, regaining convex surface in Broden's view.

The patients included in this study had been operated and followed up for at least six months. They were evaluated using functional hind foot score described by Paley et al¹². This protocol was based on subjective criteria, including pain, daily activities and work, sports and recreational activities, difficulty with walking on various surfaces, walking distance, and use of walking aids, and objective criteria, including the range of motion of the subtalar joint and ankle and the presence of a limp, see table 1. A score was assigned to each criterion. The subjective criteria were weighted as 70 percent and the objective criteria, as 30 percent. A score of 90 to 100 was considered excellent, 72 to 89 good, 41 to 71 fair, and 1 to 40 poor. Patients with excellent and good scores were satisfied. According to Paley et al, the radiological criteria which affect the clinical outcome are the height, width of calcaneus and Bohler's angle. Lateral and axial views were performed to evaluate these criteria and loss of reduction¹².

Table 1: Evaluation Protocol and Scoring System for Pain and Function of the Hindfoot¹²

Criteria	Score (Points)
Subjective	
Pain	
No pain	20
Occasional, mild pain	18
Moderated pain, necessitating occasional use of medication	10
Severe pain, necessitating regular use of medication	5
Pain at rest	0
Activities of daily living and occupation	
No change	20
Modified, without difficulty	15
Same or modified, with difficulty	10
Disabled: cannot work or perform activities of daily living	0
Sports and recreational activities	
No change	10
Modified, without difficulty	8
Same or modified, with difficulty	5
Disabled: cannot participate in sports or recreational activities	0
Walking surfaces	
Normal walking on any surface	10
Difficulty or discomfort or uneven ground, stairs, ladder, and inclines	
Slight	5
Moderate	2
Severe	0
Walking distance	
Same	5
Less than before, but more than 6 blocks	4
Less than 6 blocks	2
Around the house only	0
Walking aids	
No new walking aid or shoe insert or modification since the time of the injury	5
Insoles, heel cushions, wedges, inserts, or special shoes since the time of the injury	3
Cane, crutches, walker, or wheelchair since the time of the injury	1
Both of the two previous categories	0
Objective	
Range of motion*, Ankle	
66 to 100 per cent: 50 to 75 degrees	10
33 to 65 per cent: 25 to 49 degrees	5
0 to 32 per cent: 0 to 24 degrees	0
Subtalar joint	
66 to 100 per cent: 31 to 45 degrees	15
33 to 65 per cent: 16 to 30 degrees	10
5 to 32 per cent: 3 to 15 degrees	5
0 to 4 per cent: 0 to 2 degrees	0
Limb	
None	5
Slight	2
Moderate or sever	0

*The percentage refers to the percentage of normal or of a standard value

RESULT

The mean age was 37 years, 38 males (86%) and 6 females (14%). All patients sustained a fall from a height. Six patients had associated lumbar spine fracture which was treated conservatively. According to Soeur and Remy modification of Essex Lopresti, there were seven tongue type with mild comminution (b_1), four tongue type with moderate comminution (b_2), sixteen Joint depression type with mild comminution (c_1), thirteen joint depression type with moderate comminution (c_2), and eight severely comminuted fractures (d), see figure 6¹³. This means there were 23 (48%) fractures with mild comminution, 17 (35%) fractures with moderate comminution, and 8 (17%) severely comminuted, see figure 7.

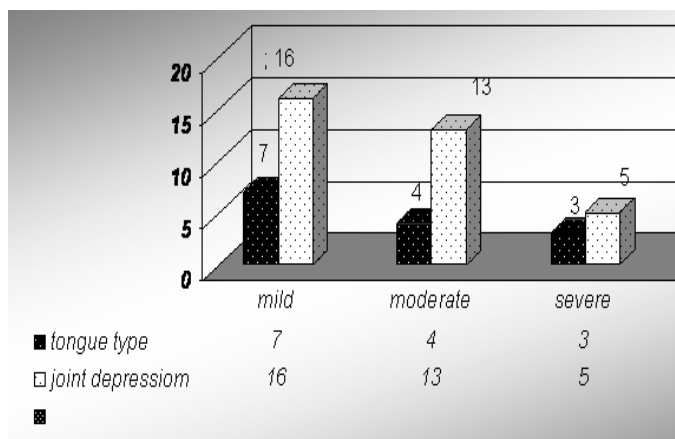


Figure 6: Incidence of Different Types of Calcaneus Fracture in Our Study

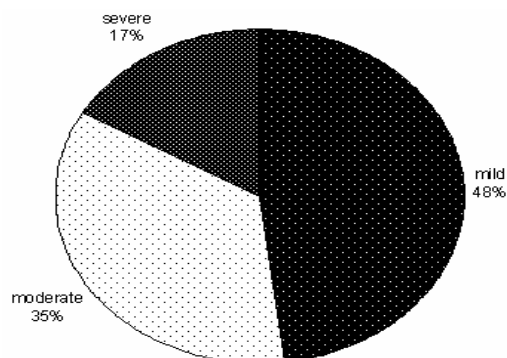


Figure 7: Incidence of Severity of Different Types of Fracture Calcaneus in Our Study According to Sour and Remy Classification

Based on the combined assessment the result were excellent in 13 (27%) fractures, good in 25 (52%), fair in 7 (15%) and poor in 3 (6%). Accordingly, satisfactory results were obtained in 79% of fractures and unsatisfactory in 21% of fractures, see figure 8.

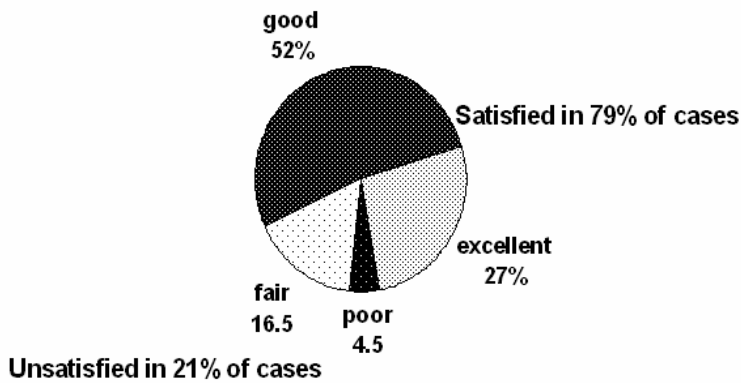

Figure 8: Overall Result of This Study

The excellent results were mainly obtained in tongue type, 11 (85%) fractures out of 13 had excellent results. Because of the small number, this is not statistically significant; however, the fracture geometry of the tongue type facilitates adequate closed reduction. This is because the calcaneal tuberosity is still attached to the lateral part of the posterior articular facet.

Two cases of superficial infection encountered and treated with antibiotics. There was no loss of achieved reduction.

DISCUSSION

The balance between the percentage of anatomical reduction and the amount of soft tissue damage should be carefully weighted in the management of fracture calcaneus especially the severely comminuted type. The choice lies between trail of full reduction with extensive soft tissue damage or reasonable reduction with minimal soft tissue insult.

Diabetics, smokers, patients with vascular impairment, compound fractures or fractures with extensive blisters and persistent swelling are not the best choice of extensile open reduction^{7,8,15}. Moreover, the extensile approach should be carried only when swelling subsides¹⁶⁻¹⁸.

Weber et al treated fifty displaced intra-articular calcaneal fractures using different methods of fixation, which resulted into higher incidence of deep infection and devascularization of the lateral wall of the calcaneus in extensile approach¹⁹. In our series, there were two cases of superficial infection, which is significantly lower than in most series of extensile open reduction are. There was no deep infection or necessity to remove the implants.

Stulik et al in their large series of 287 displaced intra-articular calcaneal fractures reported 86.2% satisfactory result using mini invasive technique¹⁵. This is similar to our study, where satisfactory results were obtained in 79% of cases. Our excellent results were mainly in tongue type of mild to moderate comminution (b₁ and b₂). Similar conclusion was reported by Tonetta in his series of 46 patients treated with percutaneous fixation^{20,21}.

CONCLUSION

In this study, operable cases of displaced intra-articular fracture of calcaneus, mild to moderate comminution were treated adequately and effectively using percutaneous screw fixation.

Minimally invasive techniques compared with the result of other methods of treatment of displaced intra-articular of calcaneus, offer the prospect of fewer complications and better outcome.

Author Contribution: All authors share equal effort contribution towards (1) substantial contributions to conception and design, acquisition, analysis and interpretation of data; (2) drafting the article and revising it critically for important intellectual content; and (3) final approval of the manuscript version to be published. Yes

Potential Conflicts of Interest: No

Competing Interest: None, **Sponsorship:** None

Submission date: 27.01.2011 **Acceptance date:** 20 April 2011

Ethical approval: Secondary Care Medical Research Subcommittee

REFERENCES

1. Eastwood DM, Langkamer VG, Atkins RM. Intra-articular Fractures of the Calcaneum. Part II: Open Reduction and Internal Fixation by the Extended Lateral Transcalcaneal Approach. *J Bone Joint Surg Br* 1993; 75(2): 189-95.
2. Böhler L. Diagnosis, Pathology, and Treatment of Fractures of the Os Calcis. *J Bone Joint Surg Am* 1931; 13: 75-89.
3. Essex-Lopresti P. The Mechanism, Reduction Technique, and Results in Fractures of the Os Calcis. *Br J Surg* 1952; 39(157): 395-419.
4. Sanders R. Current Concepts Review-Displaced Intra-articular Fractures of the Calcaneus. *J Bone Joint Surg Am* 2000; 82: 225-50.
5. Crosby L, Fitzgibbons T. Computerized Tomography Scanning of Acute Intra-Articular Fractures of Calcaneus. A New Classification System. *J Bone Joint Surg Am* 1990; 72(6): 852-9.
6. Stephenson, JR. Treatment of Displaced Intra-Articular Fractures of the Calcaneus Using Medial and Lateral Approaches, Internal Fixation, and Early Motion. *J Bone Joint Surg Am* 1987; 69(1): 115-30.
7. Zwipp H, Tscherne H, Thermann H, et al. Osteosynthesis of Displaced Intra-Articular Fractures of the Calcaneus: Results in 123 Cases. *Clin Orthop Relat Res* 1993; (290): 76-86.
8. Randle JA, Kreder HJ, Stephen D, et al. Should Calcaneal Fractures be Treated Surgically? A Meta-Analysis. *Clin Orthop Relat Res* 2000; (377): 217-27.
9. Fernandez DL, Koella C. Combined Percutaneous and "Minimal" Internal Fixation for Displaced Articular Fractures of the Calcaneus. *Clin Orthop Relat Res* 1993; (290): 108-16.
10. Sclamberg EL, Davenport K. Operative Treatment of Displaced Intra-Articular Fractures of the Calcaneus. *J Trauma* 1988; 28(4): 510-6.

11. Stephenson JR. Treatment of Displaced Intra-Articular Fractures of the Calcaneus Using Medial and Lateral Approaches, Internal Fixation, and Early Motion. *J Bone Joint Surg Am* 1987; 69(1): 115-30.
12. Paley D, Hall H. Intra-Articular Fractures of the Calcaneus. A Critical Analysis of Results and Prognostic Factors. *J Bone Joint Surg Am* 1993; 75(3): 342-54.
13. Soeur R, Remy R. Fractures of the Calcaneus with Displacement of the Thalamic Portion. *J Bone Joint Surg Br* 1975; 57(4): 413-21.
14. Burdeaux BD. Reduction of Calcaneal Fractures by the McReynolds Medial Approach Technique and Its Experimental Basis. *Clin Orthop Relat Res* 1983; (177): 87-103.
15. Stulik J, Stehlik J, Rysavy M, et al. Minimally-invasive Treatment of Intra-Articular Fractures of the Calcaneum. *J Bone Joint Surg Br* 2006; 88(12): 1634-41.
16. Essex-Lopresti P. The Mechanism, Reduction Technique and Results in Fractures of the Os Calcis. *Clin Orthop* 1993; 290: 3-16.
17. Abidi NA, Gruen GS. Operative Techniques in Open Reduction and Internal Fixation of Calcaneal Fractures. *Operative Techn in Orthop* 1999; 9: 239-46.
18. Schuler FD, Conti SF, Gruen GS, et al. Wound-healing Risk Factors after Open Reduction and Internal Fixation of Calcaneal Fractures: Does Correction of Bohler's Angle Alter Outcomes. *Orthop Clin North Am* 2001; 32: 187-92.
19. Weber M, Lehmann O, Sägerser D, et al. Limited Open Reduction and Internal Fixation of Displaced Intra-Articular Fractures of the Calcaneum. *J Bone Joint Surg Br* 2008; 90(12): 1608-16.
20. Tornetta P 3rd. The Essex-Lopresti Reduction for Calcaneal Fractures Revisited. *J Orthop Trauma* 1998; 12(7): 469-73.
21. Tornetta P 3rd. Percutaneous Treatment of Calcaneal Fractures. *Clin Orthop Relat Res* 2000; (375): 91-6.