

## **Anaesthesia Conflict for Emergency Laparoscopy Appendectomy in Cystic Fibrosis**

Yasser Mandour, MD, DESAIC\*

**A thirty-one years old gentleman presented for emergency laparoscopic appendectomy. The patient had multiple hospital admissions due to frequent respiratory tract infections associated with cystic fibrosis (CF). The patient had severe productive cough and widespread coarse crepitations and wheezes. A recent large burned area was noticed on the lumbosacral region. General anaesthesia (GA) was the only anesthetic option available for this patient to undergo the emergency laparoscopy appendectomy despite his bad chest condition. The patient was discharged home after 96 hours, following an uneventful postoperative period.**

*Bahrain Med Bull 2013; 35(2):*

On the long arm of chromosome 7 lies the CFTR (Cystic Fibrosis Transmembrane Conductance Regulator) gene, which controls the chloride ions<sup>1</sup>. CFTR gene in humans, leads to cystic fibrosis or congenital bilateral absence of vas deferens. The abnormal CFTR protein blocks the movement of chloride ions and water in and out of cells leading to abnormally thick and sticky mucous. This, in turn, affects the epithelial lining cells of the airways, pancreas and other organs as liver, GIT and reproductive organs<sup>1</sup>.

Cystic fibrosis is a fatal, genetic disease. It affects the respiratory system through the blockage of the airway and glands by thick mucous, which leads to their destruction and scarring, patchy atelectasis and chronic hypoxia. The thick mucous cannot be cleared by the cilia leading to bacterial trapping and thus chronic infection and colonization with *Pseudomonas aeruginosa*, *Staphylococcus aureus*, *Haemophilus influenza* and other gram-negative organisms and opportunistic fungal infections. Therefore, chronic dysfunction and disability results in decreased life expectancy<sup>2</sup>.

CF is considered a chronic disease, with median survival rate of 38 years<sup>3</sup>. Anesthetists might see these patients with increasing frequency; it is common nowadays to find adult CF patients presenting to surgery. For anesthetists, the perioperative management of CF patients requires a thorough understanding of the pathophysiology and clinical implications of CF, as well as the impact of the various anaesthetic techniques and medications<sup>4</sup>.

---

\*Senior Resident

Department of Anaesthesia & ICU

BDF Hospital

Kingdom of Bahrain

Email: yasseryousi1@hotmail.com

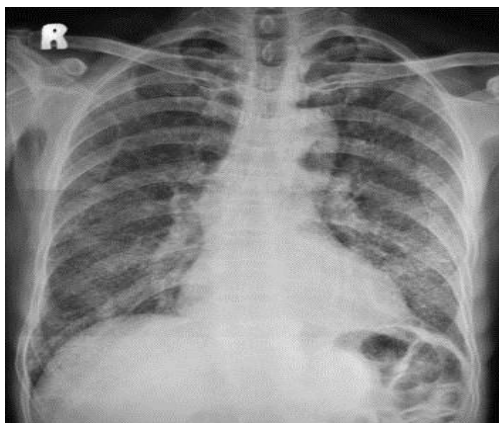
The aim of this report is to present a case of cystic fibrosis (CF) admitted for emergency laparoscopy for general anesthesia (GA) with already compromised chest condition and large burn area in the lumbosacral area.

## THE CASE

A thirty-one-year old patient with CF was scheduled for emergency laparoscopic appendectomy. Medical history showed multiple hospitalizations for recurrent chest infections. The current chest infection was marked, which was confirmed by chest X-ray. Moreover, general examination revealed large, recent burned area in the lumbosacral region, which is a contraindication to neuraxial block (spinal and epidural).

Parenteral antibiotics and bronchodilators were used preoperatively. Routine laboratory investigations (including serum lipase, LFTs, coagulation profile) were normal. ABG showed mild respiratory hypercapnia mixed with mild metabolic alkalosis. Chest X-ray showed widespread chest infection, see figure 1. Pulmonary function tests (PFTs) were not done due to the nature of emergency. Recent Echo revealed no affection of the right side of the heart.

After induction of anesthesia, the patient was positioned, prepared and draped in a sterile fashion. The inflamed appendix was excised through 2 cm supraumbilical curvilinear incision directly above the umbilicus. There was a minimal surgical bleeding.



**Figure 1: Preoperative Chest X-ray**

Intraoperatively, basic monitoring was done followed by rapid-sequence induction (RSI) and endotracheal tube (ETT) intubation, to avoid aspiration pneumonia. Heat and moisture exchanger (HME) was used to avoid further inspissation of airway secretions, because mucus secretions are already thick and viscid in CF patients. Frequent blind suction of the viscous secretions and administration of bronchodilators were done via the ETT. Ventilator settings were adjusted to compensate for the CF chest condition to keep the pressure limit below 35 mmHg (to prevent barotrauma) and to increase the I:E ratio to 1:3 (because CF is considered obstructive lung disease). Intraoperative pain control was achieved by intravenous opioids and acetaminophen. Extubation was done on table after full recovery of airway reflexes.

Postoperatively, the patient was shifted to the recovery room and kept there under observation for 6 hours for close monitoring of his vital signs. Postoperative instructions were given to maintain semi-sitting position to improve compliance of lungs and chest wall; strict pain control to facilitate ventilation and avoid splinting of the diaphragm; facemask

oxygenation of 6 liters for 6 hours to avoid hypoxemia and to encourage the use of incentive spirometry to recruit atelectatic alveoli; early ambulation was encouraged to avoid bed-ridden complications as DVT. Patient was sent home after 96 hours of uneventful postoperative period.

## DISCUSSION

Laparoscopies are becoming common surgical procedures, and it is preferably done under endotracheal GA. However, regional anesthetic techniques are used for laparoscopy, especially if there is some anesthetic risk. Rajesh SM et al reported success and safety of laparoscopic appendectomy under combined spinal-epidural anesthesia (CSE)<sup>5</sup>. The technique is mandatory especially in patients with cardiopulmonary insufficiency, which is the case in CF patients<sup>5</sup>.

However, the neuraxial block (spinal, epidural or combined) is contraindicated in patients with burns in the lumbosacral region. Mortality in extensive burns is primarily due to wound infection and septicemia, which might be attributed to the immunocompromised status of burned patients<sup>6</sup>.

In CF patients, it would be prudent to avoid GA due to the already compromised chest condition. Therefore, most anesthetists would prefer regional anesthetic techniques for CF patients.

Costello et al reported a pregnant patient with moderate-to-severe CF presented for elective Caesarian section due to Intrauterine Growth Restriction (IUGR) and persistent maternal weight loss<sup>7</sup>. She successfully delivered a low-birth weight pre-term boy under CSE<sup>7</sup>.

Galli-Tsinopoulou et al reported a successful pregnancy and delivery in a young woman suffering from CF and gestational diabetes<sup>8</sup>. She had some serious complications of CF such as mild-to-moderate pulmonary infection, exocrine pancreatic insufficiency and focal biliary cirrhosis. She successfully delivered a low-birth weight pre-term boy under epidural anaesthesia<sup>8</sup>.

Molina-Teran et al concluded that GA is safe for endobronchial biopsy (EBB) as part of fiberoptic bronchoscopy provided that these procedures are done by experienced pulmonologists and anesthetists<sup>9</sup>.

The safety of deep sedation and GA was confirmed by Wengrower et al. They had concluded that management of complicated moderately high-risk pediatric population could be done using deep sedation<sup>10</sup>. However, they highlighted the importance of the presence of all the safety criteria for ambulatory deep sedation or GA<sup>10</sup>.

In a case report of single lung transplantation for CF patient with a surgical history of previous pneumonectomy, Ji-Hyun Chung et al concluded that GA for lung transplantation was possible and safe<sup>11</sup>. However, they highlighted the necessity of meticulous review of such patients and tailoring the anesthesia plan to match the CF patients' pathological conditions. They also raised a very important issue which is the proficiency of the surgeons and their expertise in operating on such patients<sup>11</sup>.

## CONCLUSION

This case is presented to address the perioperative anesthetic management done for a cystic fibrosis patient. The anesthetic plan included preoperative optimization of the chest condition, intraoperative precautions against further impairment of patient's airway and ventilation and postoperative close monitoring of vital signs as well as instructions to prevent potential complications (especially oxygenation and ventilation).

Cystic Fibrosis is a multi-organ disease, affecting mainly the pulmonary system. Anesthetists are facing cystic fibrosis in adult patients presenting for both emergency and elective surgeries. Anaesthesia plan must be multi-disciplinary, including anesthetists, surgeons, pulmonologists, physiotherapists and nursing staff. Tailoring anesthesia for each individual patient is mandatory. The proficiency of the surgeon operating on such critical patients should be considered.

---

**Potential conflicts of interest:** None

**Competing interest:** None    **Sponsorship:** None

**Submission date:** 14 January 2013    **Acceptance date:** 24 February 2013

**Ethical approval:** Approved by anesthetic department, BDF Hospital, Bahrain.

## REFERENCES

1. Gardsby DC, Vergani P, Casandy L. The ABC Protein Turned Chloride Channel Whose Failure Causes Cystic Fibrosis. *Nature* 2006; 440(7083): 477-83.
2. Wiehe M, Arndt K. Cystic Fibrosis: A Systems Review. *AANA J* 2010; 78(3): 246-51.
3. Boyle MP. Adult Cystic Fibrosis. *JAMA* 2007; 298(15): 1787-93.
4. Huffmyer JL, Littlewood KE, Nemergut EC. Perioperative Management of the Adult with Cystic Fibrosis. *Anesth Analg* 2009; 109(6): 1949-61.
5. Mane RS, Patil MC, Kedareshvara KS, et al. Combined Spinal Epidural Anesthesia for Laparoscopic Appendectomy in Adults: A Case Series. *Saudi J Anaesth* 2012; 6(1): 27-30.
6. Tiwari VK. Burn Wound: How It Differs from Other Wounds? *Indian J Plast Surg* 2012; 45(2): 364-73.
7. Costello J, Lynch J, Byrne P, et al. Pregnancy and Cystic Fibrosis. *Ir Med J* 2008; 101(8): 254-5.
8. Galli-Tsinopoulou A, Mamopoulous A, Panagiotides M, et al. Successful Pregnancy and Delivery in a Young Woman with Cystic Fibrosis and Gestational Diabetes. *J Cyst Fibros* 2002; 1(1): 39-41.
9. Molina-Teran A, Hilliard TN, Saglani S, et al. Safety of Endobronchial Biopsy in Children with Cystic Fibrosis. *Pediatr Pulmonol* 2006; 41(11): 1021-4.
10. Wengrower D, Gozal D, Gozal Y, et al. Complicated Endoscopic Pediatric Procedures Using Deep Sedation and General Anesthesia Are Safe in the Endoscopy Suite. *Scand J Gastroenterol* 2004; 39(3): 283-6.

11. Chung JH, Cha SC, Hwang JH, et al. Anesthetic Experience in Patient for Single Lung Transplantation with Previous Contralateral Pneumonectomy-A Case Report. Korean J Anesthesiol 2012; 62(5): 479-83.