

Migrated Basilic Vein Stents

Jamal Hashem, LRCSI, LRCPI* Ghazi Y Ismael, MRCS**
Dhafer M Kamal, MSc, FRCS***

An arteriovenous fistula is the preferred vascular access for hemodialysis. Secondary thrombosis secondary to a venous stenosis is the most common complication seen with AV fistulas, and currently, percutaneous endovascular intervention (balloon angioplasty and stenting) is considered the treatment of choice for venous stenosis. Despite being less invasive than surgery, these interventions present a unique subset of potential complications with limited evidence available on optimal treatment.

We report a case of migrated basilic vein stents in a seventeen-year-old male undergoing hemodialysis through a brachiobasilic AV fistula. The complication was treated by fixing the stents to the venous wall using non-absorbable sutures. The objective was to prevent further stent migration towards the heart and thus, steer away from a probable catastrophic event.

Bahrain Med Bull 2016; 38 (2): 122 - 124

Venous stenosis is the most common complication associated with AV fistulas in adults and children in modern vascular practice; the initial modality of treatment in most cases is percutaneous endovascular intervention^{1,2}.

High-pressure balloons, cutting balloons and stents are used when dealing with venous lesions, and stenting is recommended as it prevents the expected recoil seen with venous lesions³. These interventional procedures have their unique risks and complications, such as stent thrombosis, vessel perforation, misplacement and migration^{1,2}.

The aim of this presentation is to report a safe procedure to prevent further stent migration and cardiac catastrophe.

THE CASE

A seventeen-year-old male with cerebral palsy was undergoing regular hemodialysis in the hospital via right brachiobasilic AV fistula. The end stage renal disease was secondary to severe vesicoureteric reflux.

High dynamic venous pressures were recorded during different dialysis sessions and the patient was complaining of right upper limb swelling and pain. Physical examination revealed right upper limb edema and multiple venous collaterals at the shoulder suggestive of venous hypertension secondary to a venous stenosis.

A fistulogram was performed under sedation. This revealed a flow-limiting stenosis at the distal aspect of the venous limb, see figure 1. The lesion was crossed with a Terumo Guide Wire

and catheter. Angioplasty was performed using a 12mm x 4cm balloon; this was followed by the deployment of a self-expandable stent within the stenosis 8mm x 6cm. Stent sizing was based on the operator's judgment after balloon angioplasty; ultrasonography was not used for sizing the stents.



Figure 1: Stenotic Lesion within Right Basilic Vein

The stent was clearly undersized and migrated proximally towards the thoracic cavity. Balloon angioplasty of the stent was performed using a 12mm x 4cm in an attempt to fix this stent to the vein wall. Two further stents were later deployed within the stenosis 12mm x 4cm. Unfortunately, subsequent radiographs showed active migration of the first and second stents proximally towards the thoracic cavity and the third stent remained in position, see figure 2. Hemostasis was secured with the Angio-seal device.

* Resident
** Registrar
*** Consultant Vascular and Endovascular Surgeon
Department of General Surgery
Bahrain Defense Force Hospital
Senior Lecturer, RCSI-Bahrain
Kingdom of Bahrain
Email: dhaferkamal@hotmail.com

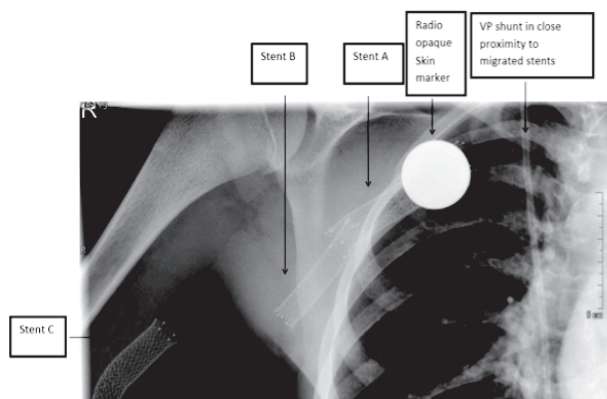


Figure 2: Chest X-ray Revealing the Position of the Migrated Stents

Both stents were noted to be actively migrating. The importance of maintaining the vascular access was of paramount importance as this patient had multiple failed left upper limb fistula procedures, and a lower limb fistula was contraindicated due to severe bilateral lower limb contractures. The stents were fixed to the vein wall with non-absorbable sutures under general anesthesia.

Stent locations were marked on the patient's skin under X-ray guidance, see figure 2. The basilic vein was exposed via a transverse right mid-arm incision and the axillary vein via a transverse right infraclavicular incision. The migrated stents were palpated and anchored to the venous wall with 3.0 Prolene sutures over a Teflon patch.

Chest X-ray was obtained on postoperative day, and then every three months for 14 months. All postoperative X-rays showed no further migration of the anchored stents, see figure 3. The patient was discharged on the first postoperative day in a good condition. His vascular access remains functioning two years after surgery.

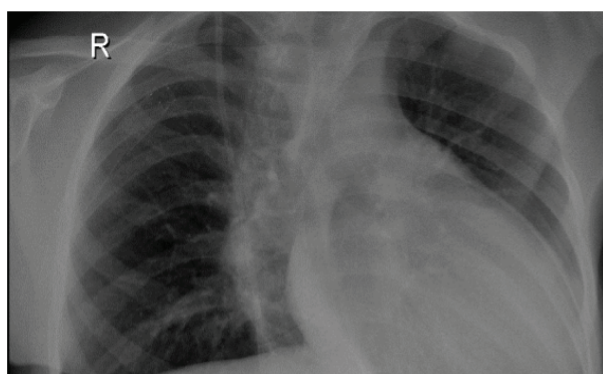


Figure 3: Chest X-ray Revealing No Further Migration of the Stents

DISCUSSION

Stent migration is a serious complication with possible life-threatening sequelae including injuries to cardiac valves or papillary muscles, resulting in valvular dysfunction, cardiac tamponade or in some cases cardiac perforation^{4,5,6}.

Malpositioning of endovascular stents or post-deployment migration may occur secondary to balloon rupture, dislodgement from the balloon, mishandling of the deployment device, under sizing the balloon and inadequate stent overlap⁷. Multiple modalities could be used for selecting the appropriate stent size, including conventional and intra-vascular ultrasonography⁷.

No guidelines are available for the management of this complication, and the available evidence comes from case reports and case series^{5,7-10}. Different percutaneous, open and hybrid techniques could be found in the literature^{5,7-10}. Percutaneous retrieval could be achieved using gooseneck snares or grasping forceps. Stent fixation is also reported with additional stent implantation or balloon angioplasty⁷. Open surgical options include direct visualization and retrieval of the stents. Reports of combined endovascular and open surgical techniques have successful results, yet no randomized trials or large case series exist. The procedure choice should be based on case circumstances and available resources and expertise¹⁰. In experienced hands, percutaneous techniques have a success rate of 90%⁹. In our case, the operator attempted fixing the stents with balloon angioplasty and further stent implantation, both of which were unsuccessful.

Multiple factors influenced our decision in this case. The endovascular option was not attempted as appropriate instruments were not available. Therefore, it was decided to fix the stents rather than to retrieve them; vessel wall trauma and the risk of dissection and/or thrombosis is a known complication of intravascular stenting; this is more likely to happen during stent manipulation⁷.

CONCLUSION

Treatment of migrated intravascular stents should be individualized and based on patient characteristics and available resources. In our case, the endovascular option was not readily available, and we report a management method that successfully prevented further stent migration while maintaining vascular access function.

Author Contribution: All authors share equal effort contribution towards (1) substantial contribution to conception and design, acquisition, analysis and interpretation of data; (2) drafting the article and revising it critically for important intellectual content; and (3) final approval of manuscript version to be published. Yes.

Potential Conflicts of Interest: None.

Competing Interest: None. **Sponsorship:** None.

Submission Date: 1 October 2015.

Acceptance Date: 2 March 2016.

Ethical Approval: Approved by Department of General Surgery, Bahrain Defense Force Hospital, Bahrain.

REFERENCES

1. Goldstein SL, Smith CM, Currier H. Noninvasive Interventions to Decrease Hospitalization and Associated Costs for Pediatric

- Patients Receiving Hemodialysis. *J Am Soc Nephrol* 2003; 14(8):2127-31.
2. Clinical Practice Recommendation 8: Vascular Access in Pediatric Patients. *Am J Kidney Dis* 2006; 48 Suppl 1:S274-6.
3. Kovalik EC, Newman GE, Suhocki P, et al. Correction of Central Venous Stenoses: Use of Angioplasty and Vascular Wallstents. *Kidney Int* 1994; 45(4):1177-81.
4. Prahlow JA, O'Bryant TJ, Barnard JJ. Cardiac Perforation Due to Wallstent Embolization: A Fatal Complication of the Transjugular Intrahepatic Portosystemic Shunt Procedure. *Radiology* 1997; 205(1):170-2.
5. Kang W, Kim IS, Kim JU, et al. Surgical Removal of Endovascular Stent after Migration to the Right Ventricle Following Right Subclavian Vein Deployment for Treatment of Central Venous Stenosis. *J Cardiovasc Ultrasound* 2011; 19(4):203-6.
6. Fazel P, Schussler JM, Berbarie, et al. Embolization of a Stent from an Arteriovenous Graft into the Right Ventricle in a Patient on Chronic Hemodialysis. *Proc (Bayl Univ Med Cent)* 2011; 24(2):94-5.
7. Gabelmann A, Krämer SC, Tomczak R, et al. Percutaneous Techniques for Managing Maldeployed or Migrated Stents. *J Endovasc Ther.* 2001; 8(3):291-302.
8. Bartorelli AL, Fabbicchi F, Montorsi P, et al. Successful Transcatheter Management of Palmaz Stent Embolization after Superior Vena Cava Stenting. *Catet Cardiovasc Diagn* 1995; 34(2):162-6.
9. Slonim SM, Dake MD, Razavi MK, et al. Management of Misplaced or Migrated Endovascular Stents. *J Vasc Interv Radiol* 1999; 10(7):851-9.
10. Bagul NB, Moth P, Menon NJ, et al. Migration of Superior Vena Cava Stent. *J Cardiothorac Surg* 2008; 3:12.