

MEDICAL QUIZ

NAJEEB JAMSHEER, MD, FRCR
U J NABAR, MD, DMRE

This 47 year old Saudi lady came with the complaint of recurrent attacks of giddiness and loss of consciousness for a few months. On clinical examination there was no neurological deficit and no evidence of papilloedema. Clinical diagnosis was late onset epilepsy. This CT examination was carried out to rule out space occupying lesion.

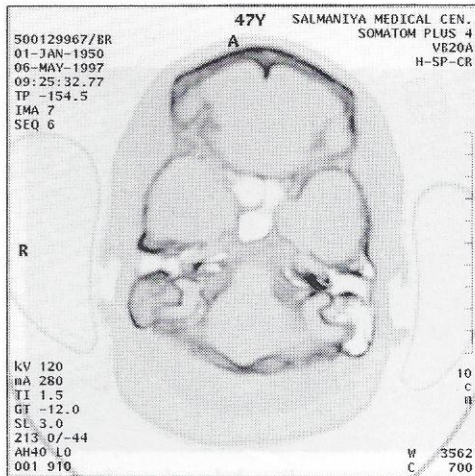


Fig A

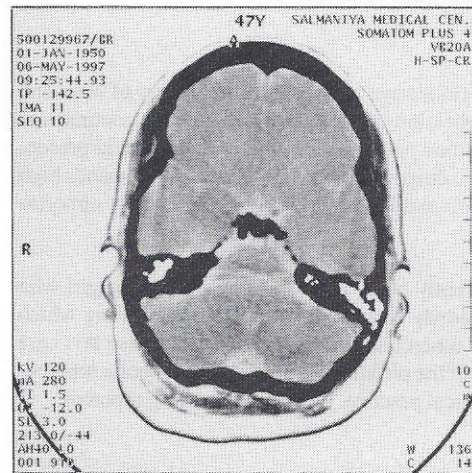


Fig B

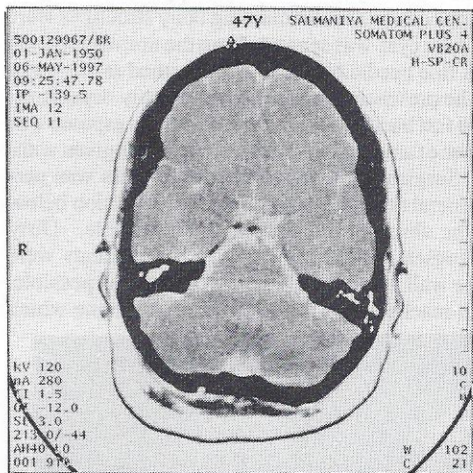


Fig C

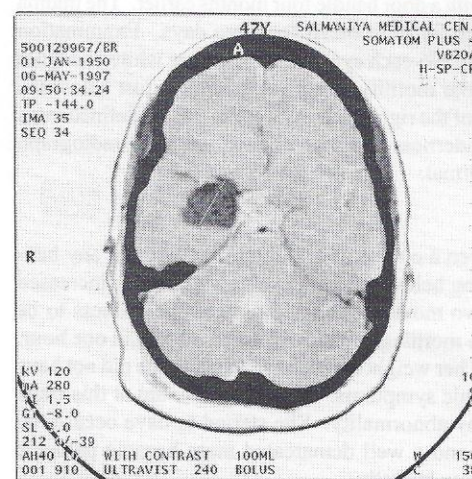


Fig D

1. Describe the lesion ? (Figures A,B & C-without IV contrast. Fig D - with IV contrast)
2. Give 3 differential diagnostic possibilities ?
3. How do "bone windows" help in the differential diagnosis of this lesion ?
4. What is your diagnosis ?

Answers on page 86