

Volar Wrist Ganglion: A Report of an Unusual Case

Eyad Alqasim, MD* Rashid Kameshki, MBBS** Maged Mostafa, MD***

A patient presented with wrist painless mass, the superficial branch of radial nerve was overlying the mass. The mass was removed surgically and the numbness disappeared postoperatively.

Ganglion cyst is a very common soft tissue condition. Its etiology remains not very well understood. The usual size is about 1-2 cm, but some atypical cysts exist. A comprehensive knowledge of the regional anatomy together with good preoperative diagnostic technique is essential for their safe excision particularly in those with unusual presentation.

Bahrain Med Bull 2012; 34(3):

Ganglion cysts are benign tumors. In the wrist, it is considered to be the most common site. There is no known definitive etiology, but it is commonly encountered due to degeneration of mucoid connective tissue.

Very often the cyst would resolve spontaneously if small. Many patients seek consultation because of the fear of malignancy and some would ask for excision¹. Surgical excision has a lower rate of recurrence compared to aspiration¹.

The aim of this report is to present an unusual case of volar wrist ganglion.

THE CASE

A seventy-six year old Bahraini woman presented to the out-patient clinic with history of swelling on the volar side of her left wrist. The condition started many years ago and has progressively increased in size over the last two months before presentation. Initially she did not suffer from any associated symptoms. Recently however, she started complaining of occasional numbness over the dorsal aspect of the thumb.

On examination, an approximately 5cm large soft, mobile, non-tender, cystic swelling was noticed on the radial side of the volar aspect of the left wrist, see figure 1 (a and b). The radial pulse was easily palpable.

* Registrar

** Senior House Officer

*** Consultant and Head

Orthopedic Department

King Hamad University Hospital

Kingdom of Bahrain

Email: rashid.kameshki@khuh.org.bh

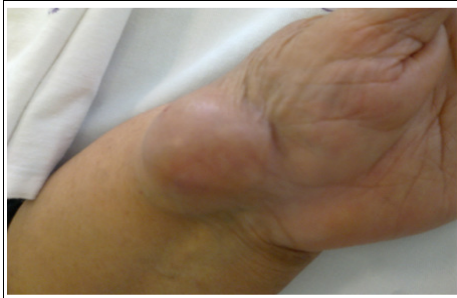

Figure 1(a):The Ganglion on the Radial Volar Aspect of the Wrist, Extending Slightly Dorsally

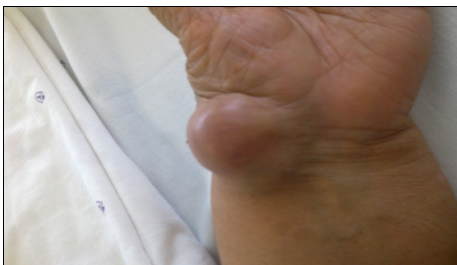

Figure 1(b): The Ganglion on the Volar Aspect

An initial diagnosis of volar ganglion was made, which was confirmed by MRI revealing a 3.2x2.9x3.6cm fluid-filled multilocular cystic mass, which is superficial to the extensor pollicis brevis and abductor pollicis longus. The cyst demonstrated a homogenous hypointense signal in T1 and a hyperintense signal in T2 suggestive of a ganglion cyst, see figures 2 and 3.

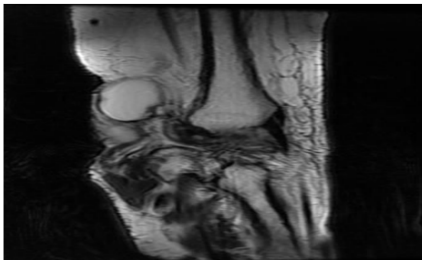


Figure 2: T2-weighted Axial View of the Left Wrist. A Fluid-filled Cystic Lesion in a Close Proximity to the Radius

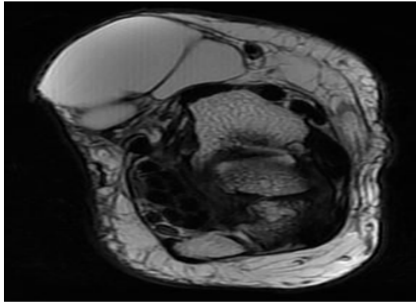


Figure 3: T2-weighted Sagittal View of the Left Wrist. The Ganglion Has 3 Lobes

Ultrasound revealed a multi-lobulated, jelly fluid-filled, avascular cystic lesion.

The lesion was removed surgically. The lesion was approached laterally by an incision 8-10 cm long. The radial neurovascular structures were identified and isolated safely. The wrist joint capsule was not involved. The superficial branch of the radial nerve was found traversing the superficial surface of the ganglion. The nerve was separated carefully and the ganglion was excised without rupture, see figure 4. The tissue was sent for histopathological, which confirmed that the ganglion was fully-excised, see figures 5 and 6.

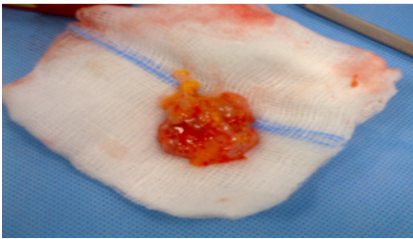


Figure 4: The Intact Ganglion Was Excised

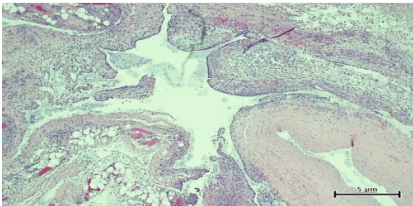


Figure 5: Loculated Cystic Lesion with Smooth Attenuated Lining, Fibrofatty Wall and Some Stellate Cells (H&E x 10)

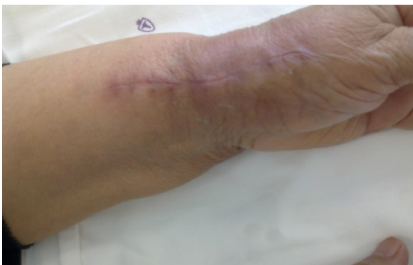

Figure 6: Healed Scar of the Surgical Incision

DISCUSSION

Ganglion cysts affect the hand and wrist; they are frequently seen in patients attending the orthopedic clinic. Women are more commonly affected than men. These lesions usually arise adjacent to joints or tendons². Dorsal wrist ganglion cysts account for 60-70% while the volar ones for 18-20%³.

Volar wrist ganglions commonly arise in the interval between the first extensor compartment and flexor carpi radialis tendon sheath, proximal to the wrist flexion crease.

The size of these lesions, whether dorsal or volar, is usually between 1-2 cm⁴. In the case reported here, a larger size was found, see figure 1. To our knowledge, only one similar case has been reported of rapidly growing thenar eminence ganglion in 85-year-old woman⁵. The cyst was also lobulated measuring 5 x 4 cm. Both cases shared the atypical age of the patient, and both patients sought medical advice due to their fear of the cyst being malignant. Hand soft tissue sarcoma is uncommon.

The cyst presents frequently as a painless, small soft tissue mass in the thenar eminence or over the dorsum, which initially remains dormant for many years but later expands rapidly. Another possible differential diagnosis is radial artery pseudoaneurysm. This was excluded in our case by the absence of bruit within the lesion and later by Doppler ultrasonography.

Volar wrist ganglions may extend deeply and compress the median and ulnar nerves depending on their location^{6,7}. In our patient, however, due to the large size of the ganglion and its slight dorsal extension over the first extensor compartment, the terminal branches of the superficial radial nerve were stretched by the swelling causing numbness over the dorsal aspect of the thumb. The numbness has improved after the surgical excision.

Damage to the palmar cutaneous branch of the median nerve and radial artery should be avoided while planning surgical incision⁸.

CONCLUSION

A patient presented with wrist painless mass, the superficial branch of radial nerve was overlying the mass. The mass was removed surgically and the numbness disappeared postoperatively.

Unusual presentations of volar wrist ganglion may be encountered in spite of the atypical age, size and extension of the swelling. The diagnosis may be established preoperatively by physical examination and MRI. Planning the surgical incision in such cases can ensure safe dissection and complete excision.

Author contribution: All authors share equal effort contribution towards (1) substantial contributions to conception and design, acquisition, analysis and interpretation of data; (2) drafting the article and revising it critically for important intellectual content; and (3) final approval of the manuscript version to be published. Yes

Potential conflicts of interest: No

Competing interest: None **Sponsorship:** None

Submission date: 4 April 2012 **Acceptance date:** 13 June 2012

Ethical approval: King Hamad University Hospital Research and Ethical Committee.

REFERENCES

1. Gude W, Morelli V. Ganglion Cysts of the Wrist: Pathophysiology, Clinical Picture, and Management. *Curr Rev Musculoskeletal Med* 2008; 1(3-4):205-11.
2. Wang AA, Hutchinson DT. Longitudinal Observation of Paediatric Hand and Wrist Ganglia. *J Hand Surg Am* 2001;26(4):599-602.
3. Angelides AC. Ganglions of the Hand and the Wrist. In: Green DP, Hotchkiss RN, Pederson WC, eds. *Operative Hand Surgery*. 4th Edn. New York: Churchill Livingstone; 1999: 2171-83.
4. Nahra ME, Bucchieri JS. Ganglion Cysts and Other Tumor Related Conditions of the Hand and Wrist. *Hand Clin* 2004; 20(3):249-60.
5. Azzopardi EA, Gujral S, Mandal A, et al. Rapidly Expanding Thenar Eminence Ganglion: A Case Report *Cases Journal* 2009;2:129.
6. Kobayashi N, Koshino T, Nakazawa A, et al. Neuropathy of Motor Branch of Median or Ulnar Nerve Induced by Midpalm Ganglion. *J Hand Surg Am* 2001; 26(3):474-7.
7. Okada K, Miyake J, Katoaka T, et al. Median Nerve Neuropathy in the Forearm due to Recurrence of Anterior Wrist Ganglion that Originates from the Scaphotrapezial Joint. *Case Report. J Brachial Plex Peripher Nerve Inj* 2012; 7(1):1.
8. Dias J, Buch K. Palmar Wrist Ganglion: Does Intervention Improve Outcome? *J Hand Surg* 2003; 28(2): 172-6.