

## **Misdiagnosed Case of Lepromatous Leprosy**

Ahmed Anwer Aljowder, BSc, MD\* Azad Kareem Kassim FRCPI, FRCP (Glasg), FAAD\*\*  
Mazen Raees MB, BCh, BAO, LRCP & SI (NUI), FACHARZT\*\*

### **ABSTRACT**

**Despite of tremendous decrease in cases of leprosy world-wide due to the successful anti-mycobacterial agents, some areas still remain endemic for this infectious disease globally<sup>1</sup>.**

**The Kingdom of Bahrain and other GCC countries are not considered as endemic areas for leprosy, but the Ministry of Health and National Registry Records show sporadic cases among expatriates<sup>1</sup>.**

**We report a case of lepromatous leprosy in a fifty-six-year-old non-Bahraini female misdiagnosed as chronic urticaria for the past 10 years. She was treated with Dapsone, Rifampicin and Clofazimine according to WHO management protocol.**

---

\* Senior House Officer

\*\*Consultant

Department of Dermatology

King Hamad University Hospital

Kingdom of Bahrain

Email: ahmed.aljowder@khuh.org.bh

### **INTRODUCTION**

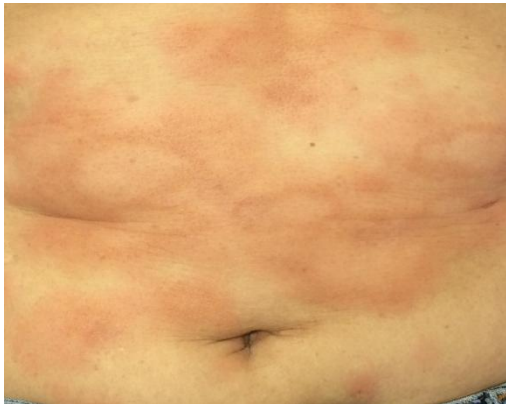Leprosy is a contagious disease. It is chronic systemic granulomatous disease (CGD) caused by mycobacterium leprae. The mode of transmission is through direct contact, and it is known for its long incubation period that has been reported to be from 2-40 years (commonly 5-7 years); usually it is acquired during childhood or young adulthood<sup>2</sup>. The disease presents with a broad clinical, immunological and bacteriological spectrum; at one pole is the tuberculoid leprosy (TL) and on the other is lepromatous leprosy (LL), a third form is the borderline or dimorphic leprosy (BL) which has hybrid characteristics and features of both tuberculoid and lepromatous leprosy.

The organism reproduces maximally at 27°C to 30°C; therefore, the features of the disease are usually seen in cooler parts of the skin, peripheral nerves, anterior chamber of the eye, upper respiratory tract, and testes; it spares warmer areas of the skin (axilla, groin, scalp, and midline of the back)<sup>3</sup>. Skin manifestations and nerve involvement are seen in all forms of leprosy, but vary in presentation, distribution of the lesions and severity of the presenting picture. The diagnosis is usually based on clinical suspicion and is confirmed through bacteriological and histopathological analysis. The differential diagnoses are sarcoidosis, leishmaniasis, lupus vulgaris, NTM infection, lymphoma, syphilis, yaws, granuloma annulare, and necrobiosis lipoidica<sup>3</sup>. The most commonly used drugs to treat leprosy are dapsone, rifampicin and clofazimine, but the antimicrobial regimen varies based on the underlying form of leprosy<sup>4,5</sup>.

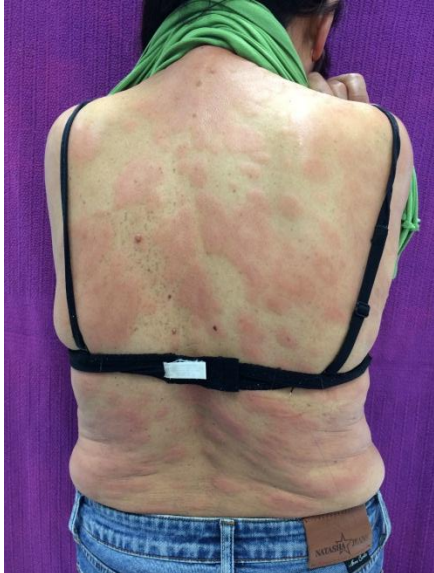## THE CASE

A fifty-six-year-old non-Bahraini Filipino woman was working as a housemaid and nanny in Bahrain for the last 10 years. The patient is not a known case of any medical illness; she was referred from the health center to the dermatology department as case of uncontrolled allergic urticaria for more than 9 years, presented with a history of worsening diffuse erythematous papules/nodules that has become more pruritic, dry, and scaly. Patient was treated at the health center with multiple topical medications ranging from low potency topical steroids to super potent topical steroids and on regular anti-histamines, the patient showed no improvement.

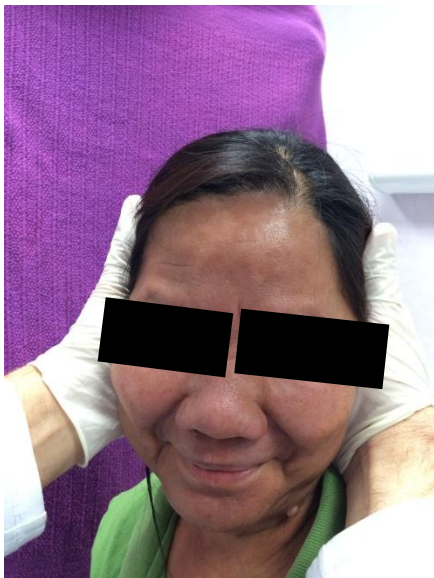On examination, multiple well-demarcated, bilateral symmetrically distributed infiltrated erythematous nodules and plaques, involving the ear lobes, arms, buttocks, trunk, and the face resulting in the pathognomonic leonine face with loss of lateral eyebrow hair, see figures 1, 2, and 3. Nerve involvement was noted with enlargement of peripheral nerves (ulnar) with positive peripheral neuropathy on fine touch for tactile sensation.



**Figure 1: Ill-Defined Papules on the Abdomen, with Well-Defined Hypopigmented, Slightly Scaling Anesthetic Macules on the Abdomen**



**Figure 2: Well-Demarcated, Infiltrated, Erythematous Plaques and Macules on the Back**

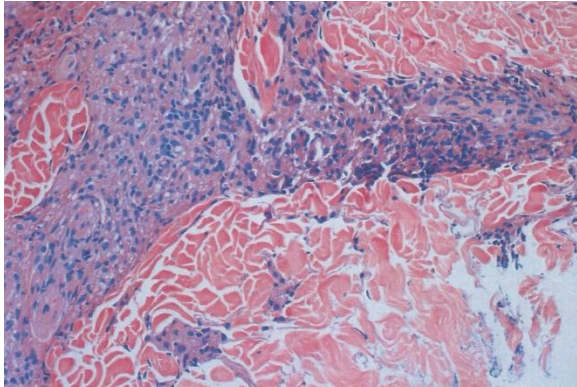


**Figure 3: Leonine Face with Loss of Lateral Eyebrow Hair**

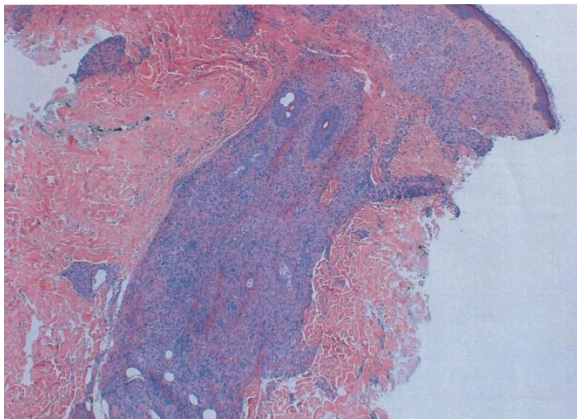
A skin biopsy was done; the sample was taken from the abdomen. The biopsy showed marked dermal replacement by sheets of histiocytic proliferation along with scattered ill-defined, non-necrotizing dermal micro-granulomas, see figures 4 and 5. Part of the inflammation showed typical perineural infiltration. Wade Fite stain confirmed the presence of numerous acid-fast bacilli in parasitized macrophages, see figure 6.

The diagnosis of lepromatous leprosy was made and the Public Health Directorate was notified; the patient was referred to Salmaniya Medical Complex to start a course of conventional anti-

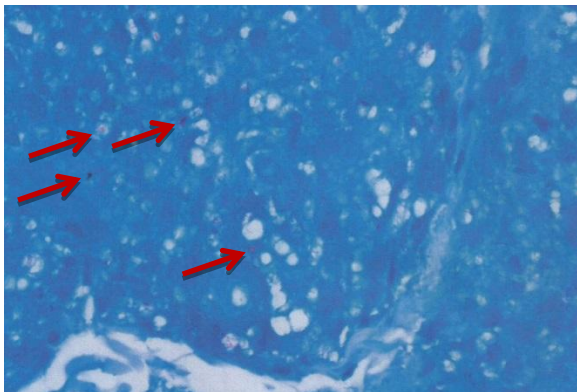
leprosy treatment regimen (Dapsone, Rifampicin and Clofazimine) according to the protocol management recommended by WHO.



**Figure 4: Non-Necrotizing Micro Granulomas and Perineural Infiltration by Histiocytes**



**Figure 5: Perineural and Peri-appendageal Inflammatory Cell Infiltrate**



**Figure 6: Wade-Fite Stain Demonstrated many Intracellular Acid Fast Bacilli (Dark purple in Stain)**

## DISCUSSION

Leprosy was called Hansen's disease; it is a contagious and chronic systemic granulomatous disease caused by mycobacterium leprae, an acid fast bacillus that involves the skin and peripheral nerves. Males are more affected than females, 600,000 new cases reported annually; more than 80% of cases are in India, China, Myanmar, Indonesia, Brazil, and Nigeria. From 2011, four new cases are reported annually in Bahrain<sup>1</sup>. The disease presents with a broad clinical, immunological and bacteriological spectrum<sup>3,6</sup>.

Leprosy could be described as tuberculoid leprosy (TL) characterized by localized skin involvement and/or peripheral nerve involvement; few organisms are present in the skin biopsies, clinically could be seen as anesthetic hypopigmented macules; nerve involvement (ulnar, peroneal, and greater auricular) might lead to atrophy, contracture, and pain, in severe cases corneal ulceration and blindness. Lepromatous leprosy (LL) characterized by generalized involvement including skin, upper respiratory mucous membrane, the reticuloendothelial system, adrenal glands, and testes; many bacilli are present in tissue; the skin lesions are variable, nerve involvement is less pronounced compared to others. Borderline "Dimorphic" leprosy (BL) characterized by the following features of both tuberculoid and lepromatous leprosy. Usually many bacilli present, varied skin lesions; macules and papules. Usually it progresses to TL or regresses to LL; axilla, groin, palms, and plantar surfaces are usually spared. Nerve involvement is much less than the previous two. Skin manifestations and nerve involvement are seen in all forms of leprosy<sup>3,6</sup>.

The most commonly used drugs to treat leprosy are dapsone, rifampicin and clofazimine, but the antimicrobial regimen varies based on the underlying form of leprosy<sup>2,5</sup>.

Our patient had classical clinical and histological features of lepromatous leprosy; she was misdiagnosed for the past 10 years as case of chronic allergic urticaria, recent statistics showed an increase number of reported cases of leprosy in non-Bahraini immigrants in Bahrain<sup>1</sup>.

Our case was misdiagnosed for 10 years which raises the issue of close contact with children and family members and the possibility of transmission of infection; therefore, the Public Health Directorate was informed to screen all contacts with the affected individual.

## CONCLUSION

**A case of lepromatous leprosy in a fifty-six-year-old non-Bahraini female misdiagnosed as chronic urticaria for the past 10 years. She was treated with Dapsone, Rifampicin and Clofazimine according to WHO management protocol.**

**Family physicians should be vigilant in dealing with patients with suspicious clinical features of leprosy who originated from countries where the disease is prevalent. Proper screening, diagnosis, and referral to dermatologist should be done.**

---

**Author Contribution:** All authors share equal effort contribution towards (1) substantial contributions to conception and design, acquisition, analysis and interpretation of data; (2)

drafting the article and revising it critically for important intellectual content; and (3) final approval of the manuscript version to be published. Yes.

**Potential Conflicts of Interest:** None.

**Competing Interest:** None.

**Sponsorship:** None.

**Submission Date:** 1 July 2014.

**Acceptance Date:** 6 July 2014.

**Ethical Approval:** Approved By the Research and Ethics Committee, King Hamad University Hospital, Bahrain.

## REFERENCES

1. World Health Organization. Leprosy: Fact Sheet. Available at: [http://www.searo.who.int/entity/leprosy/topics/fact\\_sheet/en/](http://www.searo.who.int/entity/leprosy/topics/fact_sheet/en/). Accessed in January 2014.
2. Singh P, Cole ST. Mycobacterium Leprae: Genes, Pseudogenes and Genetic Diversity. *Future Microbiol* 2011; 6(1):57-71.
3. Wolff K, Johnson RA, Suurmond R. Fitzpatrick's Color Atlas & Synopsis of Clinical Dermatology. New York: McGraw-Hill, 2005; 655-61.
4. Scollard DM, Joyce MP, Gillis TP. Development of Leprosy and Type 1 Leprosy Reactions after Treatment with Infliximab: A Report of 2 Cases. *Clin Infect Dis* 2006; 43(2):e19-22.
5. World Health Organization. Surveillance of Drug Resistance in Leprosy: 2009. *Wkly Epidemiol Rec* 2010; 85(29):281-4.
6. Gelber RH. Leprosy (Hansen's disease). In: Kasper DL, Braunwald E, Hauser S, et al. *Harrison's Principles of Internal Medicine*. 16<sup>th</sup> ed. New York: McGraw-Hill, 2005: 966-72.