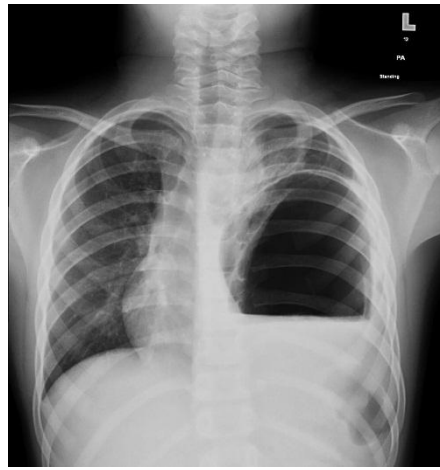


Medical Quiz

Hind Zaidan, MBBS* Martin Corbally, MB, BCh, BAO, MCh, FRCSI, FRCSEd, FRCS,
MRCPI(Assoc), Grad Dip (Risk Management), CCST (Paed Surgery)**

A nine-year-old male presented with complaints of acute pain localized to the left chest and upper abdomen. There was a history of mild abdominal trauma (un-witnessed) 2 weeks prior to the presentation.



- Q1. Describe the findings of the chest x-ray.
- Q2. What is the diagnosis and how do you confirm it?
- Q3. How do you manage this patient?

Answers on page No.....

-
- * Senior House Officer
Department of Pediatric Surgery
- ** Chief of Staff
Consultant Pediatric Surgeon
Professor & Chairman Department of Surgery, RCSI-MUB
King Hamad University Hospital
Kingdom of Bahrain
Email: hind.zaidan@khuh.org.bh